

Pei Fang Neoh, Evelyn LM
Tai, Liza-Sharmini AT

Choroidal Melanoma – A Silent Killer

Department of
Ophthalmology, School of
Medical Sciences, Health
Campus Universiti Sains
Malaysia, Kubang Kerian,
16150 Kota Bahru,
Kelantan, Malaysia

Received 16 June 2017.
Revised 19 Sept 2017.
Accepted 25 Sept 2017.
Published Online 01 Dec 2017

Abstract— A 65-year-old lady complained of occasional flashes of light over her left eye for 2 months. She was referred for ocular assessment after she underwent refractive assessment at the optometrist. On examination, best corrected visual acuity in both eyes was 6/9. Both eyes anterior segments were normal, with normal intraocular pressure. The pupils were equal with no relative afferent pupillary defect. Left eye fundus examination was normal. On the contrary, the "normal" right eye fundus examination revealed a huge, well-circumscribed hypo-pigmented elevated choroidal mass. B scan ultrasonography of the right eye showed a mushroom-shaped intraocular mass. Magnetic resonance imaging showed an intraocular lesion. Comprehensive systemic examination and investigations to rule out distant primary malignancy were unremarkable. A provisional diagnosis of right eye primary choroidal melanoma was made. Despite good vision in the affected eye, she underwent right eye enucleation in view of the large intraocular mass. The diagnosis was confirmed by histopathological examination.

*Corresponding author:
Neoh Pei Fang
E-mail: pfneoh@hotmail.com

Keywords - choroidal melanoma, enucleation

1 INTRODUCTION

Choroidal melanoma is the most common primary intraocular malignancy in adults. However, it is rare in Asians. Large choroidal melanomas are often symptomatic. We report a case of incidental early detection of choroidal melanoma in an asymptomatic eye.

2 CASE REPORT

A 65-year-old lady with no medical disease complained of occasional flashes of light over her left eye for 2 months. She did not have blurring of vision, scotoma or floaters. She was moderately myopic and presbyopic. She had no history of ocular trauma or surgery. She was referred for ocular assessment when she underwent her refractive assessment at the optometrist.

On examination, best corrected visual acuity in both eyes was 6/9. Both eyes anterior segments were normal, with normal intraocular pressure. The pupils were equal and reactive, with no relative afferent pupillary defect. Her left eye fundus examination was normal. Examination of the posterior segment of the "normal" right eye revealed a huge, well-circumscribed hypo-pigmented elevated choroidal mass in the superior retina, sparing the macula (Figure 1).

Minimal drusenoid-like deposits were noticed adjacent to the mass.

B scan ultrasonography of the right eye showed a mushroom-shaped intraocular mass with a highly reflective anterior border and orbital shadowing (Figure 2). Fundus fluorescein angiography showed double circulation with extensive leakage and late staining of the lesion (Figure 3). Magnetic resonance imaging demonstrated an intraocular lesion measuring 1.5cm (antero-posterior) x 0.7cm (width), with no extraocular extension (Figure 4). Comprehensive systemic examination and investigations to rule out distant primary malignancy were unremarkable. A provisional diagnosis of right eye primary choroidal melanoma was made.

Despite good vision in the affected eye, she was counselled on right eye enucleation in view of the large intraocular mass. The diagnosis was confirmed by histopathological examination of the enucleated eye which showed mixed cell type choroidal melanoma with no scleral and optic nerve extension. During the two years in which patient was followed up at our center, no evidence of primary tumour or distant metastasis was noted.

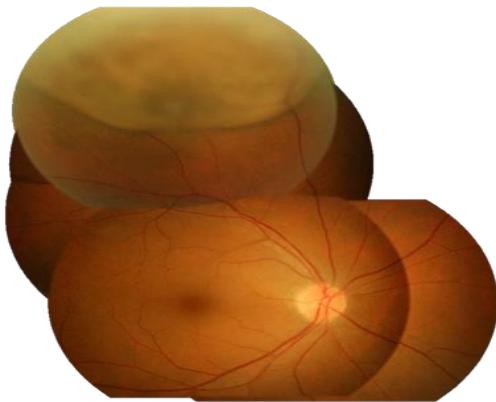


Figure 1: Right eye fundus examination revealed a large, well-circumscribed hypo-pigmented elevated choroidal mass in the superior retina.

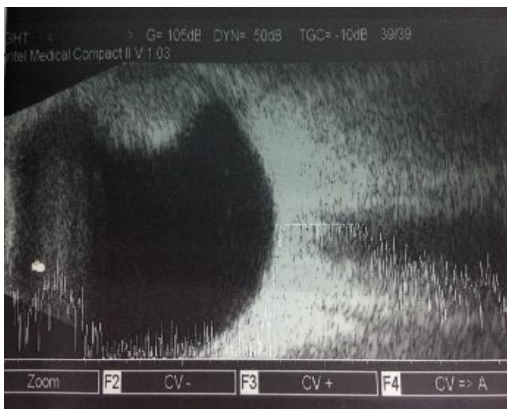


Figure 2: Right eye B scan ultrasonography of the right eye showed a mushroom-shaped intraocular mass.

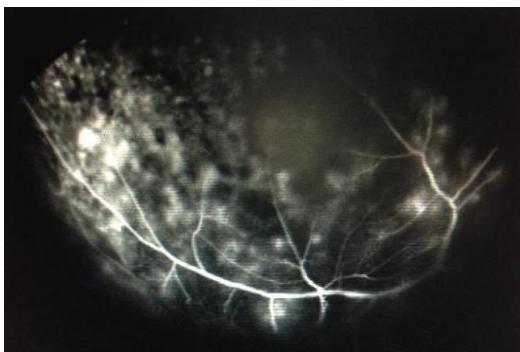


Figure 3: FFA demonstrated classical double circulation supporting the diagnosis of choroidal melanoma.

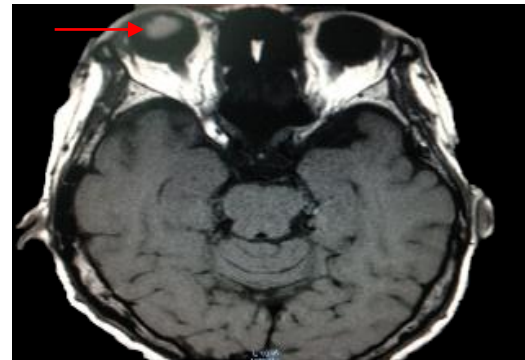

Figure 4: Magnetic resonance imaging showed an intraocular lesion (arrow).

3 DISCUSSION

Choroidal melanoma is a disease with a high mortality rate, irrespective of the chosen treatment modality. Approximately 50% of patients die of their disease [1]. Mortality is usually secondary to distant metastases, and the risk is greatest in larger tumours [2]. The majority of patients with uveal melanoma experience a degree of visual loss caused by the tumour or its treatment. Almost 30% of all patients require enucleation as primary treatment or after unsuccessful conservative therapy [3].

Although 30% of choroidal melanomas are asymptomatic; the main complaints in symptomatic cases are blurred vision (37.8%), photopsia (8.6%), and floaters (7.0%) [4]. Choroidal melanomas may remain silent for prolonged periods of time especially if anteriorly or peripherally-located. Thus, they are often found incidentally during dilated funduscopy [4].

The management of choroidal melanoma depend on various factors, such as the size of the tumour and the presence of metastases. Treatment modalities which can preserve the globe or retain the vision include radiotherapy, trans-scleral resection, and transpupillary thermotherapy [5]. However, for large choroidal melanomas, enucleation is still the mainstay of treatment as there have been no clinical trials evaluating the effectiveness of therapies other than enucleation [6], and larger tumours are associated with a greater risk of metastases [2].

4 CONCLUSION

Time constraints in a busy clinic should never be an excuse for an incomplete eye examination (i.e.

only examining the eye with the visual complaint), as not all eye conditions are symptomatic. This case reinforces the importance of comprehensive and bilateral eye assessment in aiding early detection of a possible sight- or life-threatening ocular disease.

CONFLICTS OF INTEREST

The authors report no conflicts of interest. The authors alone are responsible for the content and writing of the paper.

ACKNOWLEDGEMENT

The authors would like to thank all those in the ophthalmology and radiology team who participated in this patient's management.

REFERENCES

- [1] Kujala E, Mäkitie T, Kivelä T. Very long-term prognosis of patients with malignant uveal melanoma. *Invest. Ophthalmol. Vis. Sci.* 2003;44(11):4651-4659.
- [2] Damato BE, Heimann H, Kalirai H, Coupland SE. Age, survival predictors, and metastatic death in patients with choroidal melanoma: tentative evidence of a therapeutic effect on survival. *JAMA ophthalmology.* 2014;132(5):605-613.
- [3] Damato B, Lecuona K. Conservation of eyes with choroidal melanoma by a multimodality approach to treatment: an audit of 1632 patients. *Ophthalmology.* 2004;111(5):977-983.
- [4] Damato EM, Damato BE. Detection and time to treatment of uveal melanoma in the United Kingdom: an evaluation of 2384 patients. *Ophthalmology.* 2012;119(8):1582-1589.
- [5] Bell DJ, Wilson MW. Choroidal melanoma: natural history and management options. *Cancer Control.* 2004;11(5):296-303.
- [6] Margo CE. The collaborative ocular melanoma study: an overview. *Cancer Control.* 2004;11(5):304-309.