

Wen-Jeet Ang<sup>1,2,\*</sup>, Raja-Omar Raja-Norliza<sup>2</sup>, Abdul-Jalil Fadzillah<sup>2</sup>, Embong Zunaina<sup>1</sup>

<sup>1</sup>Department of Ophthalmology, School of Medical Sciences, Health Campus, Universiti Sains Malaysia, 16150 Kubang Kerian, Kelantan, Malaysia

<sup>2</sup>Department of Ophthalmology, Melaka General Hospital, 75400 Melaka, Malaysia

## Contact Lens Related *Elizabethkingia meningoseptica* Keratitis- A First Southeast Asean Case Report & Literature Review.

**Abstract**— We describe the first clinical case of contact lens related corneal ulcer caused by *Elizabethkingia meningoseptica* registered in Southeast Asia. A 20-year-old female student who was a regular soft contact lens wearer, presented with pain, photophobia and blurring of vision of the right eye for 3 days. On slit lamp examination, there was a small paracentral anterior stromal infiltrate with an overlying epithelial defect. Microbiological cultures from corneal scrapings, contact lens and its casing were positive for *E. meningoseptica*. Due to high likelihood of contact lens contamination causing keratitis, topical fortified gentamicin 0.9% and ceftazidime 5% were administered empirically. Topical vancomycin 5% was later added tailoring to the culture and sensitivity of the organism. After 8 weeks of treatment, the keratitis subsided and corneal epithelial defect completely healed with residual corneal opacity. Even though uncommon, contact lens related *E. meningoseptica* keratitis can occur in healthy immunocompetent individuals with no ocular comorbidities.

Received 07 Jan 2017.  
Revised 13 Feb 2017.  
Accepted 10 March 2017.  
Published Online 01 June 2017

**Keywords**— Contact lens, Cornea and external disease, *Elizabethkingia meningoseptica*, Keratitis

\*Corresponding author:  
Ang Wen Jeet  
E-mail: [wenjeat@gmail.com](mailto:wenjeat@gmail.com)

### 1 INTRODUCTION

*Elizabethkingia meningoseptica* is an environmentally ubiquitous, non-fermenting, non-motile, oxidase-positive gram-negative aerobic bacillus that is commonly found in freshwater, saltwater and soil [1]. It was first described by King in 1959 [1]. This organism is known to survive in harsh living conditions such as salt water and chlorine-treated municipal water supplies [2,3]. Yet, it is widely distributed in different geographical areas, habitats and can be commensals in fish and frogs, but not as human microflora [1,4]. Several case reports have shown that it has low virulence and is rarely a pathogenic organism in humans [5,6]. However, this opportunistic organism can lead to an array of problems such as meningitis, endocarditis, cellulitis, sepsis, abdominal abscess, peritonitis, endophthalmitis and keratitis mainly affecting the immunocompromised hosts and newborns [2,7,8].

We describe the first clinical case of corneal ulcer caused by *E. meningoseptica* registered in Southeast Asia.

### 2 CASE REPORT

A 20-year old Malay female college student was referred to us from the community health center for right eye pain and redness for the past three days. It was associated with epiphora, photophobia and blurring of vision. She has been wearing monthly silicone hydrogel contact lens for the past 1 year to correct her moderate myopia. She used multipurpose contact lens solution for disinfecting, cleaning and storing of the contact lens. She denied using her contact lens longer than 6 hours. She claimed she had frequently changed her contact lens and its solution. She denied any ocular or systemic problem, history of recent trauma or surgery to her eye. She also denied any history of swimming with contact lens or using tap water to clean or store them. On further questioning, she revealed that she habitually placed her contact lens casing and solution bottles on top of the basin-wash sink in the toilet.

On examination, her right eye best corrected visual acuity was 6/36 and 6/6 in the left eye. Slit lamp biomicroscopy examination showed a hyperemic right conjunctiva (Figure 1) and a paracentral anterior stromal infiltrates with

ill-defined margins of approximately 1.4 x 1.8 mm (Figure 2) with an overlying epithelial defect. However, there was no perineural ring infiltrates seen. Anterior chamber examination showed presence of mild anterior chamber inflammation without hypopyon. Intraocular pressure was normal. There was no posterior segment abnormalities. Anterior and posterior segments examination was sound in the fellow eye.

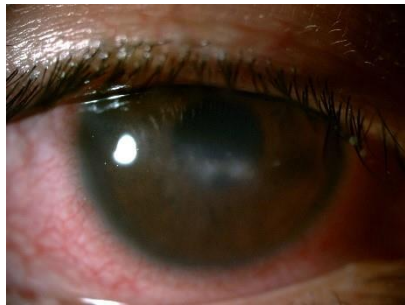

Figure 1: Right eye showed hyperemic conjunctiva

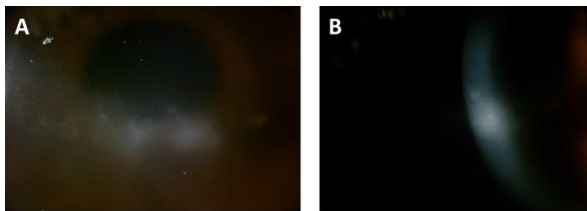


Figure 2: Right eye showed paracentral anterior stromal infiltrates with ill-defined margins.

The diagnosis of right eye microbial keratitis related to contact lens was made and corneal scraping was conducted. Corneal scraping, contact lens solution and its casing were sent for grams staining, giemsa staining and microbiological cultures. She was started on topical Ceftazidime 5% and topical fortified gentamicin 0.9 % half hourly instillation. Topical homatropine 2% and artificial tears drops were started to prevent synechiae formation and facilitate healing. Her symptoms improved after 2 days of treatment but stromal infiltrates and epithelial defect persisted.

Direct wet film microscopy and giemsa stain was negative for *Acanthamoeba* spp and fungi. Gram-negative rods were detected on grams staining. Cultures and sensitivity of the corneal smear and contact lens casing with solution showed prominent growth of yellowish white colonies on blood agar plates but not on MacConkey culture plate. The isolate was subsequently confirmed as *E. meningoseptica*, which was resistant to chloramphenicol, ceftazidime, gentamicin, tobramycin and

imipenem and sensitive to trimethoprim/sulfamethoxazole, vancomycin and rifampin.

Topical vancomycin 5% every half hourly was then started. One week after instillation of vancomycin, there was regression of circumcorneal hyperemia and anterior chamber inflammation with signs of corneal re-epithelization. There was reduction of the diameter of stromal infiltrates. During subsequent follow up, epithelial defect was fully re-epithelized with resolution of the corneal edema and corneal infiltrates, leaving behind a faint nebulous scar. Topical antibiotics were tapered down with clinical resolution of her keratitis. Topical dexamethasone 0.1% four times a day was added later. After eight weeks of treatment her visual acuity improved to 6/9.

### 3 DISCUSSION

*E. meningoseptica* has the ability to withstand chlorine-treated urban water supplies, often colonizing hospital sink basins, taps, saline, drug solutions and even intensive care equipment [2-5]. However, it has low virulence. It is commonly an opportunistic organism attributed to outbreaks involving newborns and immuno-compromised hosts from all age groups [2]. In premature infants, it is commonly associated with meningitis [7,8].

Ocular infections caused by *E. meningoseptica* are extremely rare and is usually associated with ocular morbidities. There were several reports on *E. meningoseptica* causing endophthalmitis and keratitis [7,9-15]. It was first reported by LeFrancois and Baum in 1976 [7], in a 78-year-old woman who had severe bullous keratopathy post trabecular trephination and complicated extracapsular cataract extraction. She then underwent a penetrating keratoplasty which was complicated with *E. meningoseptica* endophthalmitis. Two other cases of endophthalmitis caused by *E. meningoseptica* were reported from a single center, where both had histories of predisposing trauma to the eye [9,10].

On the other hand, several cases of keratitis associated with *E. meningoseptica* had been reported [11-15]. Three of the cases developed keratitis following trauma, radiotherapy and blepharitis [11-13].

**Table I:** Chronologically reported cases of *E. meningoseptica* ocular infections contact lens over the wash-basin which could

Author/Year	Age/Gender	Predisposing Risk	Disease	Treatment	Outcome
LeFrancois & Baum 1976 [7]	78/ Female	POAG on topical pilocarpine Trabecular trephination Post ECCE Bullous keratopathy Penetrating Keratopathy	Endophthalmitis	Topical Chloramphenicol, polymyxin sulfate, and carbenicillin sodium Oral Bactrim	Phthisical eye
Bloom A et al 2003 [13]	48/ Male	Blepharitis	Keratitis	Not stated	VA 6/7.5
Li EY & Jhanji V 2003 [11]	52/ Female	Radiotherapy Dry eye syndrome	Keratitis	Topical vancomycin	Massive lipid keratopathy VA – HM
Essex et al 2004 [9]	71/ Male	Trauma	Endophthalmitis	Vitrectomy Intravitreal vancomycin, ceftazidime and dexamethasone	Resolved inflammation VA – not stated
Connell P et al 2011 [10]	41/ Male	Depression Self inflicted ocular trauma	Endophthalmitis	Vitrectomy Intravitreal ceftazidime and vancomycin	VA 6/60
Erdem et al 2013 [12]	45/ Female	Trauma	Keratitis	Topical moxifloxacin Oral Bactrim	Resolve with scarring VA – not stated
Yang YS et al 2013 [15]	24/ Male	Contact lens Extended wear Handling of contact lens - not stated	Keratitis	Topical gatifloxacin	VA 6/6
Beato JN et al 2016 [14]	47/ Male	POAG on 4 antiglaucoma Semi-rigid contact lens	Keratitis	Topical levofloxacin and gentamicin	Healed VA - not stated
Current study	20/ Female	Contact lens Placement of casing on toilet wash-basin	Keratitis	Topical vancomycin	Resolution with residual nebulous scar VA 6/9

Our thorough literature review revealed that there were two reported cases of contact lens related keratitis caused by *E. meningoseptica* [14,15]. The first case reported by Beato et al. [14], was in a patient that had been on long term topical antiglaucoma. This might have changed the ocular surface integrity of the cornea and predisposed it to an infection. On the contrary, Yang et al. [15] reported the first healthy host with no ocular comorbid that developed keratitis, attributed possibly to the extended wear and poor handling of the contact lenses. Table I summarizes 8 reported cases of *E. meningoseptica* ocular infection from 1976-2016.

In our patient, none of the predisposing risk factors were present except for the storage of

lead to cross contamination. In view of the positive culture from the corneal scrapings, contact lens storage casing and solution, we are able to determine that the isolate is the contaminant and direct cause of her keratitis. Most cases of contact lens related keratitis were associated with contamination of contact lens storage cases, frequency of storage case replacement, hygiene, and solution type [16,17].

In addition, contact lens wearers are predisposed to corneal infection due to slowing of corneal epithelial homeostasis by suppression of cell proliferation, impairing cell migration, and reducing the rate of cell exfoliation [18-21]. A recent study by Robertson, found that multipurpose lens solution can also lead to changes in the ocular surface that may pose a

risk for keratitis [22]. We assume that combination of these factors may lead to keratitis. To the best of our knowledge, this is the first case of contact lens related keratitis associated with *E. meningoseptica* reported in Southeast Asia.

#### 4 CONCLUSION

Although, *E. meningoseptica* is rare causative agent for ocular infections, its sequelae can be devastating especially in eyes with predisposing ocular comorbidities. However, its recent emergence as an omnipresent and potentially devastating ocular pathogen for healthy hosts shouldn't be overlooked.

#### CONFLICTS OF INTEREST

The authors report no conflicts of interest. The authors alone are responsible for the content and writing of the paper.

#### REFERENCES

- [1] King EO. Studies on a group of previously unclassified bacteria associated with meningitis in infants. *Am J Clin Pathol.* 1959; 31:241-247.
- [2] Bloch KC, Nadarajah R, Jacobs R. *Chryseobacterium meningosepticum*: an emerging pathogen among immuno-compromised adults: report of 6 cases and literature review. *Medicine.* 1997; 76(1):30-41.
- [3] Chiu CH, Waddington M, Greenberg D, Schreckenberger PC, Carnahan AM. Atypical *Chryseobacterium meningosepticum* and meningitis and sepsis in newborns and the immunocompromised. *Emerg Infect Dis.* 2000; 6(5):481-486.
- [4] Hoque SN, Graham J, Kaufmann ME, Tabaqchali S. *Chryseobacterium (Flavobacterium) meningosepticum* outbreak associated with colonization of water taps in a neonatal intensive care unit. *J Hosp Infect.* 2001; 47(3):188-192.
- [5] Gungor S, Ozen M, Akinci A, Durmaz R. A *Chryseobacterium meningosepticum* outbreak in a neonatal ward. *Infect Control Hosp Epidemiol.* 2003; 24(8):613-617.
- [6] Adachi A, Mori T, Shimizu T, Yokoyama A, et al. *Chryseobacterium meningosepticum* septicemia in a recipient of allogeneic cord blood transplantation. *Scand J Infect.* 2004; 36:539-540.
- [7] LeFrancois M, Baum JL. *Flavobacterium endophthalmitis* following keratoplasty: use of a tissue culture medium-stored cornea. *Arch Ophthalmol.* 1976; 94(11):1907-1909.
- [8] Ceyhan M, Yildirim I, Tekeli A, Yurdakok M, Us E, et al. A *Chryseobacterium meningosepticum* outbreak observed in 3 clusters involving both neonatal and non-neonatal pediatric patients. *Am J Infect Control.* 2008; 36(6):453-457.
- [9] Essex RW, Charles PG, Allen PJ. Three cases of post-traumatic endophthalmitis caused by unusual bacteria. *Clin Experiment Ophthalmol.* 2004; 32(4):445-447.
- [10] Connell PP, Wickremasinghe S, Devi U, Waters MJ, Allen PJ. Self-induced *Elizabethkingia meningoseptica* endophthalmitis: A case report. *J Med Case Rep.* 2011; 5: 303.
- [11] Li EY, Jhanji V. Massive lipid keratopathy after *Elizabethkingia meningosepticum* keratitis. *Cont Lens Anterior Eye.* 2014; 37(1):55-56.
- [12] Erdem E, Abdurrahmanoglu S, Kibar F, Yagmur M, Koksal F, et al. Posttraumatic keratitis caused by *Elizabethkingia meningosepticum*. *Eye Contact Lens.* 2013; 39(5):361-363.
- [13] Bloom AH, Perry HD, Donnenfeld ED, et al. *Chryseobacterium meningosepticum* keratitis. *Am J Ophthalmol.* 2003; 136(2):356-357.
- [14] Beato JN, Espinar MJ, Figueira L, Eremina YO, Ribeiro M, et al. *Elizabethkingia meningoseptica* and contact lens use. *Acta Med Port.* 2016; 29(4):287-289.
- [15] Yang YS, Chun JW, Koh JW. Keratitis with *Elizabethkingia meningoseptica* occurring after contact lens wear: A Case Report. *Korean J Ophthalmol.* 2013; 27(2):133-136.
- [16] Stapleton F, Edwards K, Keay L, Naduvilath T, Dart J, et al. Risk factors for moderate and severe microbial keratitis in daily wear contact lens users. *Ophthalmology.* 2012; 119(8):1516-1521.
- [17] Cheng KH, Leung SL, Hoekman HW, Beekhuis WH, Mulder PG, et al. Incidence of contact-lens-associated microbial keratitis and its related morbidity. *Lancet.* 1999; 354(9174):181-185.
- [18] Ladage PM, Ren DH, Petroll WM, Jester JV, Bergmanson J, et al. Effects of eyelid closure and disposable and silicone hydrogel extended contact lens wear on rabbit corneal epithelial proliferation. *Invest Ophthalmol Vis Sci.* 2003; 44(5):1843-1849.
- [19] Ladage PM, Jester JV, Petroll WM, Bergmanson J, Cavanagh HD. Vertical movement of epithelial basal cells towards the corneal surface during use of extended-wear contact lenses. *Invest Ophthalmol Vis Sci.* 2003; 44(3):1056-1063.
- [20] Ladage PM, Yamamoto K, Ren DH, Li L, Jester JV, et al. Effects of rigid and soft contact lens daily wear on corneal epithelium, tear lactate dehydrogenase, and bacterial binding to exfoliated epithelial cells. *Ophthalmology.* 2001; 108(7):1279-1288.
- [21] Stapleton F, Kasses S, Bolis S, Keay L. Short term wear of high Dk soft contact lenses does not alter corneal epithelial cell size or viability. *Br J Ophthalmol.* 2001; 85(2):143-146.
- [22] Robertson DM. The effects of silicone hydrogel lens wear on the corneal epithelium and risk for microbial keratitis. *Eye Contact Lens.* 2013; 39(1):67-72.