

Hwang Zhen Shan¹, Juhara Haron^{1,5*}, Maya Mazwin Yahya^{2,5}, Tengku Ahmad Damitri Al-Astani Tengku Din^{3,5}, Wan Faiziah Wan Abdul Rahman^{4,5}

¹Department of Radiology, School of Medical Sciences, Universiti Sains Malaysia, Kelantan, Malaysia

²Department of Surgery, School of Medical Sciences, Universiti Sains Malaysia, Kelantan, Malaysia

³Department of Chemical Pathology, School of Medical Sciences, Universiti Sains Malaysia, Kelantan, Malaysia

⁴Department of Pathology, School of Medical Sciences, Universiti Sains Malaysia, Kelantan, Malaysia

⁵Breast Cancer Awareness and Research Unit, Hospital Universiti Sains Malaysia, Kubang Kerian, Kelantan

Received 22 Jan 2020

Revised 18 May 2020

Accepted 30 May 2020

Published Online 15 Dec 2020

*Corresponding author:

Juhara Haron.

E-mail: drjuhara@usm.my

Breast cancer in young pregnancy: A management dilemma

Abstract— Breast cancer in young pregnancy is a breast cancer diagnosed in a young lady at the age of less than 30 years old during pregnancy. Diagnosis and treatment of breast cancer during pregnancy are challenging as both maternal and fetal outcome must be considered in terms of their short and long-term effects. It requires multidisciplinary treatment. Instead, pregnancy should be preserved whenever possible, while treating the underlying breast cancer. It is important not to compromise the treatment of breast cancer because of the pregnancy. The overall therapeutic concept basically depends on timing of delivery, staging of the underlying disease, treatment mode and the impacts of treatment recommended as well as foetal outcome in relation to treatment that administered to the mother during pregnancy. We present a case of young pregnant lady at the age of 23 with breast cancer as it is a rare event and the challenges encountered in managing her and to highlight the treatment options for the patient and the baby.

Keywords — Young pregnancy, Breast cancer, Breast cancer management.

1 INTRODUCTION

Breast cancer in young pregnancy is rare. The average age of a patient with a pregnancy-associated breast cancer is between 32 and 38 years old [1]. Less than 1% of breast cancer occur before the age of 30 years [2]. Diagnosis is challenging in pregnant patients and diagnostic delays are common due to the breast changes in pregnancy impeding detection. It was stated that the mammary microenvironment in pregnancy might become tumour-promoting due to remodelling of the mammary gland. This remodelling was associated with pro-inflammatory and wound-healing mechanisms which contributed to tumour-cell dissemination. [3]. Pregnancy in women with a previous diagnosis of breast cancer is a second issue. As the majority of pregnancy-associated breast

cancer (PABC) patients and pregnancies occur in women < 40 years, *BRCA* gene mutations are over-represented in this group. In women in their 20s, approximately 33% of breast cancers will be due to genetic mutations. This number decreases to 22% in women in their 30s [4]. The diagnostic and therapeutic concepts is to preserve pregnancy while treating breast cancer. However, the management of pregnant patients with breast cancer is complex which involves optimizing maternal treatment and chances of survival, whilst minimizing the risks to the foetus. Careful considerations should be considered because it concerns not only toxicity to the mother, but short and long-term consequences for the fetus as well. Other considerations include the timing of delivery, the potential for nursing, and concerns for future fertility.

2 CASE REPORT

A healthy 23-year-old Malay lady with no underlying medical illness, presented with painless right breast lump for 1 year duration. The lump which was felt at the upper outer quadrant about a thumb size and slowly increased in size. She denied history of constitutional symptoms. There was no family history of breast cancer. On general examination, she was well and not cachexic. Clinically, a mass felt at upper outer quadrant of the right breast. It was hard and fixed with irregular surface. The size was 5 cm x 5 cm. However, the overlying skin was normal. The nipple appeared retracted. The left breast was normal.

Ultrasound of the breast showed a poorly defined heterogenous hypoechoic lesion at 12 o'clock position, about 3 cm from the nipple. The lesion measured 2.8 cm (AP) x 2.6 cm (width) (Figure 1A). There was increased in peripheral vascularity. On shear wave elastography (SWE), the maximum stiffness was 69.2 kPa as compared to surrounding normal breast tissue which measured 20.8 kPa (Figure 1B). There was no axillary lymphadenopathy.

Based on ACR BI-RADS® Atlas Fifth Edition (2013), the lesion was classified as stage 4C, high suspicion of malignancy with probability between >50% to <95%.

She underwent a core needle biopsy of right breast lesion. Histopathological examination revealed an invasive carcinoma of no special type (NST) characterised by the presence of infiltrating malignant tumour in small nests within the desmoplastic stroma. The tumour was positive for oestrogen receptor (ER) (Figure 3C) and progesterone receptor (PR) and negative for human epidermal growth factor receptor 2 (HER2).

A contrast-enhanced CT thorax for staging showed heterogeneously enhancing right upper outer quadrant breast lesion measured 3.9 cm (AP) x 5.3 cm (width) (Figure 2A) with enlarged ipsilateral axillary node continuous with lateral fascia of pectoralis muscle (Figure 2B). There was no evidence of distant metastases. Based on American Joint Committee on Cancer (AJCC) tumour-node-metastasis (TNM) staging system for breast cancer (7th edition), this patient was diagnosed as stage 3a at that time (T3N1M0).

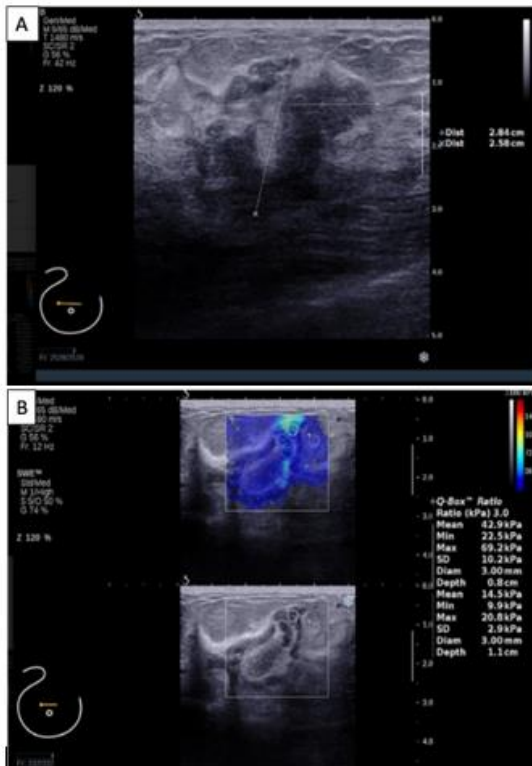


Figure 1: A. Ultrasound of the right breast shows a heterogenous hypoechoic mass with poorly defined margin and posterior acoustic shadowing. B. Shear wave elastography shows that the lesion is significantly stiffer than the normal surrounding breast tissue.

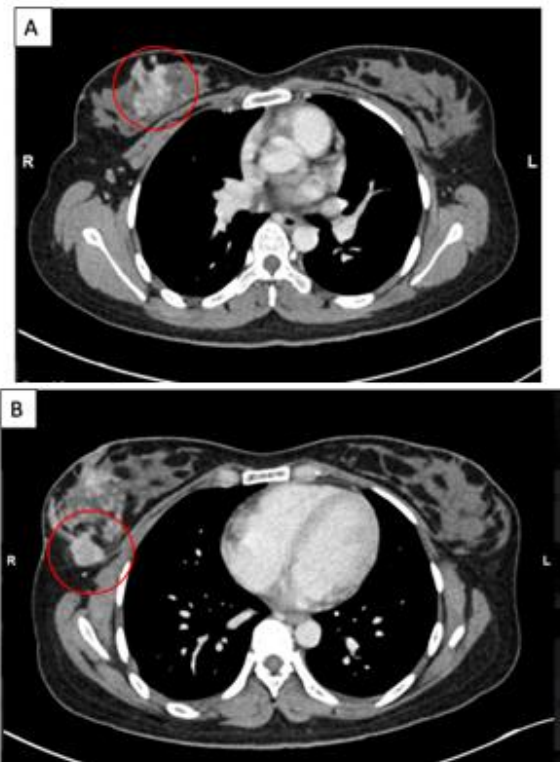


Figure 2: Axial CT thorax. [A] A well-defined heterogenous enhancing lesion at right upper outer quadrant with spiculated margin. The mass has clear fat demarcation with right pectoralis muscle. [B] An enlarged right axillary node seen in continuity with lateral fascia of pectoralis muscle.

She was planned for right total mastectomy and axillary clearance as well as immediate reconstruction by the managing team but defaulted surgery. Patient was indecisive for operation and wished for homeopathy and taking herbal drinks as alternative treatment. She was pregnant one year later. During her 18 weeks of gestation she was then subjected to right total mastectomy and axillary clearance at 20 weeks of gestation. BRCA test was not performed due to financial difficulties.

The histopathological examination from the excised breast revealed an invasive carcinoma of no special type (NST) with 35% ductal carcinoma in-situ (DCIS) component (Figure 3A). Based on modified Bloom Richardson grading, the tumour was in Grade 2. Sixteen out of 31 axillary lymph nodes were involved by a tumour (Figure 3B) with pathological staging of pT3N3aMx. Her initial HPE from the biopsy revealed positivity of ER and PR, 80% each. However, her subsequent excised tissue revealed ER negative and PR had reduced expression to 10% positive.

At gestation, she noticed her breast lesion had increased in size. Clinical examination on her second visit revealed a hard, right breast lump measuring 8 cm x 6 cm at the upper outer quadrant associated with retracted nipple. CT scan was not performed during her pregnancy in view of risk of radiation to the fetus.

She was given a combination of 3 cycles of doxorubicin and cyclophosphamide at 20 weeks until 31 weeks of gestation. She delivered at 32 weeks plus 5 days period of gestation through uneventful spontaneous vertex delivery (SVD) after completed 3 cycles of chemotherapy. She delivered a healthy baby girl weighing 1.64 kg and good Apgar score. At the time of this article was written, she has completed a total of 6 cycles of chemotherapy and 15 cycles of radiotherapy to the chest wall. No hormonal treatment was given after chemoradiation. Repeated CT thorax, abdomen and pelvis performed about 1 year following mastectomy revealed post-surgical changes with no evidence of local recurrence or distal metastases. Her baby was growing well with good developmental milestones.

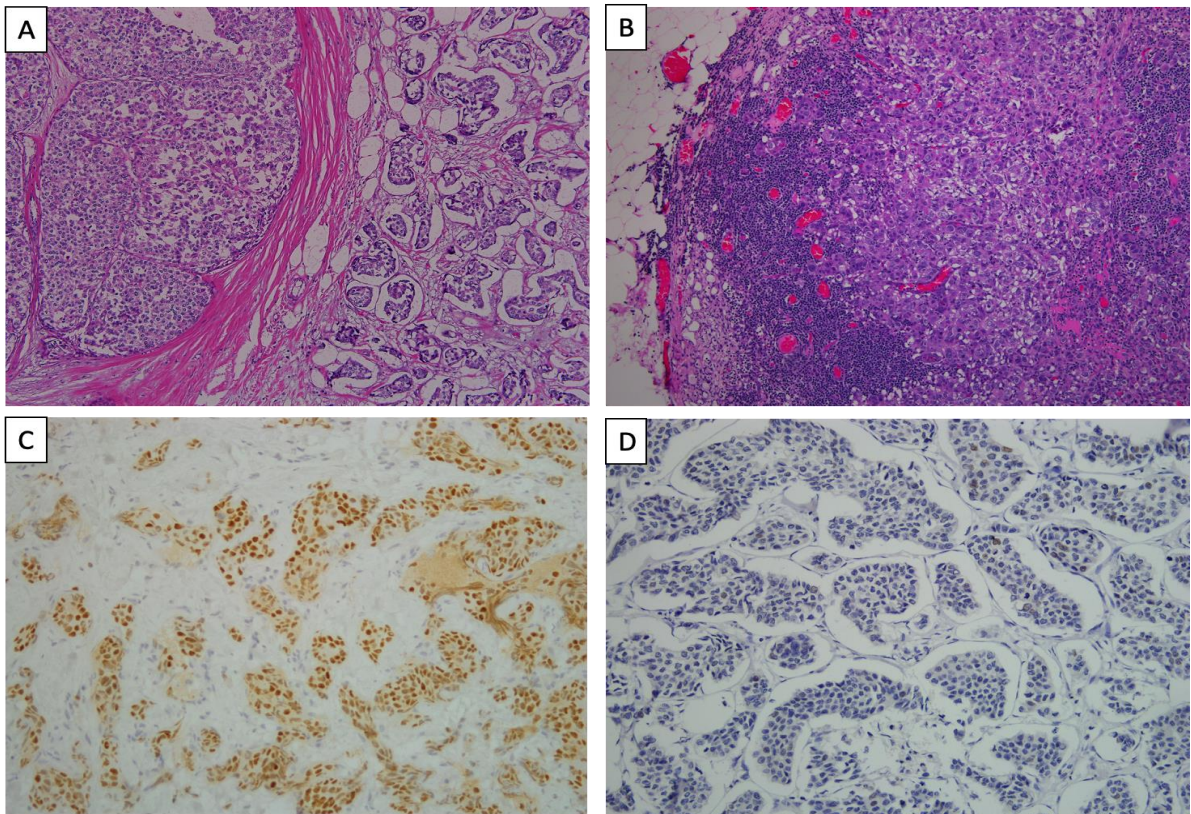


Figure 3: Histopathological examination findings. [A] Invasive tumour cells arranged in nests surrounded by retraction artefacts within desmoplastic stroma (right side) and ductal carcinoma in-situ component moderate to high grade with solid pattern (left side) (H&E stain, x100). [B] Note one of the axillary lymph nodes shows metastatic deposit (H&E stain, x100). [C] Estrogen receptor immunohistochemical stain is strongly positive in core needle biopsy tissue (IHC stain, x200). [D] Estrogen receptor immunostaining is negative in excised tissue (IHC stain, x200) (Figure 3D) and PR become reduced expression to 10%.

3 DISCUSSION

Managing breast cancer in pregnancy requires multidisciplinary effort. Treatment decision is based on the individual's tolerance for risk to herself and her fetus, disease stages and aggressiveness of the tumour at gestational time. Majority of the patients are symptomatic during presentation. Ultrasound is preferred as the first imaging modality of choice as it does not carry radiation risk and is readily available. Sonographic findings are predominantly hypoechoic mass with irregular margins and posterior acoustic shadowing, similar in our patient [5].

Mammography is not advisable during pregnancy because it carries low inherent radiation dose, which can be reduced by fetal shielding. The absorbed radiation dose to the fetus from mammogram with abdominal shield is 0.04mGy [6].

Surgery is the primary treatment of choice for early stage (stage 1 and 2) breast cancer.

Chemotherapy is contraindicated during the first trimester. Chemotherapy poses risk to fetus in first trimester especially during implantation and organogenesis. It is contraindicated during the first trimester because of the possible damage to organogenesis. The risk of congenital malformations ranges from 10 - 20% in the first trimester, whilst it drops to 1.3% in the third trimester of pregnancy. Exposure to chemotherapy during the first trimester is associated with a high incidence of spontaneous abortion and fetal malformations [7,8].

Chemotherapy poses a serious risk to the fetus in early pregnancy, during implantation and organogenesis. In the second and third trimester, chemotherapy is generally safe but may be associated with low birthweight.

Encouraging data were published on the administration of chemotherapy safely during the second and third trimester [9]. Fetal malformation risk in second and third trimester are not different than the fetuses that are not exposed to chemotherapy during pregnancy [10]. Most low birthweight cases were reported due to intrauterine growth retardation and premature delivery [11]. Chemotherapy during pregnancy should not be given after 35 weeks of pregnancy or within 3 weeks of planned delivery to avoid the potential for haematologic complications during delivery. Concomitant maternal and infant leucopenia is observed when chemotherapy is administered less than 3 weeks before delivery. Therefore chemotherapy is not recommended

beyond 35 weeks gestation in order to minimize the risk of maternal or infant neutropenia, sepsis and haemorrhage in either the mother or foetus [12,13].

Doll *et al.* reported a 16% risk of malformations with first-trimester chemotherapy versus a 1.3% risk later in pregnancy [14]. Our patient received chemotherapy during second and third trimester. Fortunately, her child was healthy with no congenital anomalies.

Hormonal and chest wall irradiation are contraindicated during pregnancy. Radiotherapy should be avoided until after delivery. Radiotherapy is not offered in pregnancy due to its teratogenic effect such as induction of childhood malignancies and haematological disorders. It was also reported to be associated with mental retardation in the fetus [15].

Hormone treatment is also not recommended during pregnancy [13,16]. If indicated, it is recommended to start after delivery or after completion of chemotherapy. There were reports on congenital craniofacial anomalies with in utero tamoxifen exposure [17].

There was a discrepancy between ER and PR hormonal expression from the biopsy and excised tissue. Both ER and PR were 80% positive in biopsy tissue whereas in the excised tissue, the ER became negative and the PR expression dropped to 10%. This change could possibly be due to pregnancy related changes or poor fixation as patient did not receive any hormonal therapy.

Most studies found that PABC was associated with decreased hormone receptor positivity [18,20]. However, this apparent increase in the incidence of ER negative breast cancer during pregnancy was probably artifactual and related to the high levels of oestrogen seen during pregnancy [1]. Another cause of hormonal alteration was due to poor tissue fixation which always occur in tissue excision. The optimal fixation should be 24 - 48 hours with slicing done to allow perfusion of the fixative substance. In short, the longer fixation will allow a better antigen retrieval.

4 CONCLUSION

Management of pregnancy in breast cancer is complicated. The treatment needs for tailored strategies, outweigh benefits and risks. Breast cancer during pregnancy remains a challenge for clinicians and a difficult experience for women and the families. Delay in diagnosis and treatment are common. The management of

breast cancer in pregnancy requires effort of multidiscipline team to offer the best option to the patient. With thoughtful application of available therapies, outcome can be optimized for both the mother and her child.

ETHICAL CLEARANCE

Prior the submission, this case report was approved by local ethics committee

CONFLICT OF INTEREST

None. The authors are responsible for the content and writing of the paper.

CONSENT

Informed consent was obtained from patient.

FUNDS

This study did not receive any special funding.

ACKNOWLEDGEMENTS

This manuscript was produced without any financial support from any organization. Many thanks to co-authors for contribution making this manuscript successfully produced.

REFERENCES

- [1] Jones AL. Management of pregnancy-associated breast cancer. *The breast*. 2006;15:S47- S52.
- [2] Albain KS, Allred DC, Clark GM. Breast cancer outcome and predictors of outcome: are there age differentials. *J Natl Cancer Inst Monogr*. 1994;16(16):35-42.
- [3] Schedin P. Pregnancy-associated breast cancer and metastasis. *Nat Rev Cancer*. 2006;6(4):281-91.
- [4] Keyser EA, Staat BC, Fausett MB, Shields AD. Pregnancy-associated breast cancer. *Rev Obstet Gynecol*. 2012;5(2):94-9.
- [5] Ahn BY, Kim HH, Moon WK, Pisano ED, Kim HS, Cha ES, et al. Pregnancy-and lactation-associated breast cancer: mammographic and sonographic findings. *Journal of ultrasound in medicine*. 2003;22(5):491-7.
- [6] Kopans D. The altered breast: pregnancy, lactation, biopsy, mastectomy, radiation, and implants. *Breast Imaging*, 2nd ed Philadelphia: Lippincott-Raven. 1998:445-7.
- [7] Ring AE, Smith IE, Jones A, Shannon C, Galani E, Ellis PA. Chemotherapy for breast cancer during pregnancy: an 18-year experience from five London teaching hospitals. *Journal of clinical oncology*. 2005;23(18):4192-7.
- [8] Azim Jr HA, Peccatori FA, Pavlidis N. Treatment of the pregnant mother with cancer: a systematic review on the use of cytotoxic, endocrine, targeted agents and immunotherapy during pregnancy. Part I: solid tumors. *Cancer Treat Rev*. 2010;36:101-9.
- [9] Yu H, Cheung P, Leung R, Leung T, Kwan W. Current management of pregnancy-associated breast cancer. *Hong Kong Med J*. 2017;23(4):387-94.
- [10] Amant F, Vandenbroucke T, Verheeecke M, Fumagalli M, Halaska MJ, Boere I, et al. Pediatric outcome after maternal cancer diagnosed during pregnancy. *New England Journal of Medicine*. 2015;373(19):1824-34.
- [11] Pavlidis N, Pentheroudakis G. The pregnant mother with breast cancer: diagnostic and therapeutic management. *Cancer Treat Rev*. 2005;31(6):439-47.
- [12] Zemlickis D, Lishner M, Degendorfer P, Panzarella T, Burke B, Sutcliffe SB, et al. Maternal and fetal outcome after breast cancer in pregnancy. *American Journal of Obstetrics & Gynecology*. 1992;166(3):781-7.
- [13] Loibl S, Von Minckwitz G, Gwyn K, Ellis P, Blohmer JU, Schlegelberger B, et al. Breast carcinoma during pregnancy: international recommendations from an expert meeting. *Cancer: Interdisciplinary International Journal of the American Cancer Society*. 2006;106(2):237-46.
- [14] Doll DC, Ringenberg QS, Yarbrow JW. Antineoplastic agents and pregnancy. *Semin Oncol*. 1989;16(5):337-46.
- [15] Zagouri F, Psaltopoulou T, Dimitrakakis C, Bartsch R, Dimopoulos M-A. Challenges in managing breast cancer during pregnancy. *Journal of thoracic disease*. 2013;5(Suppl 1):S62.
- [16] Loibl S. New therapeutic options for breast cancer during pregnancy. *Breast Care*. 2008;3(3):171-6.
- [17] Berger JC, Clericuzio CL. Pierre Robin sequence associated with first trimester fetal tamoxifen exposure. *American Journal of Medical Genetics Part A*. 2008;146(16):2141- 4.
- [18] Bonnier P, Romain S, Dilhuydy JM, Bonichon F, Julien JP, Charpin C, et al. Influence of pregnancy on the outcome of breast cancer: A case-control study. *International journal of cancer*. 1997;72(5):720-7.
- [19] Merkel DE. Pregnancy and breast cancer. *Semin Surg Oncol*. 1996;12(5):370-5.
- [20] Elledge RM, Ciocca DR, Langone G, McGuire WL. Estrogen receptor, progesterone receptor, and HER-2/neu protein in breast cancers from pregnant patients. *Cancer*. 1993;71(8):2499-506.