

Joanne Shalini CR^{1,3} Nor
Hasnida AG, MD² Ahmad
Nurfahmi AA³, Fazliana I¹,
Aidila JJ³, Khairidzan MK³

¹Ophthalmology Department,
Universiti of Malaya, Petaling
Jaya, Selangor, Malaysia

²Ophthalmology Department,
Hospital Tengku Ampuan
Afzan, Kuantan, Pahang,
Malaysia

³Ophthalmology Department,
Kulliyah of Medicine,
International Islamic
University,
25200 Kuantan, Pahang,
Malaysia

Received 26 Sept 2018.

Revised 21 Nov 2018.

Accepted 10 Dec 2018.

Published Online 05 Jan 2019

Iatrogenic Corneal Injury Secondary to Trypan Blue usage during cataract surgeries: A Case Series

Abstract— To report clinical features and management of toxic keratopathy induced by inadvertent intrastromal trypan blue injection (0.06%) during cataract surgery. We report two cases of toxic keratopathy induced by iatrogenic intrastromal trypan blue injection during cataract surgery. The two cases were performed by ophthalmology residents at our centre. Intraoperatively in both cases, trypan blue dye was inadvertently injected into the corneal stroma via side port wound. Surgery was abandoned due to development of corneal oedema. They were treated as toxic keratopathy due to the bluish discoloration of the cornea, generalized (limbal to limbal) panstromal edema and marked Descemet membrane folds. There were epithelial microbullae and mild circumferential injection. Both patients' vision deteriorated with only minimal anterior chamber reaction and normal intraocular pressure. Intensive topical corticosteroid, prophylactic antibiotic, gutt hypertonic saline 5%, and cycloplegic agent eyedrops were given. The corneal edema and staining in both patients resolved completely by 6 weeks. They underwent uncomplicated elective phacoemulsification 3 months after the incident. Intraoperative iatrogenic inadvertent intrastromal trypan blue injection during cataract surgery can cause toxic keratopathy. A decision to abandon the surgery and prompt management to reverse the complication can produce excellent outcome.

*Corresponding author:
Joanne Shalini Chewa Raja
E-mail: joanneshalini@gmail.com

Keywords — Intrastromal, toxic keratopathy, trypan blue.

1 INTRODUCTION

Trypan blue (TB) is one of the most commonly used dye in ophthalmology surgeries. It has been a popular choice among anterior segment surgeons mainly due to the safety profile, ease of availability, and ability to stain the anterior capsule [1]. It is particularly helpful in situations where the red reflex is poor such as in asteroid hyalosis and vitreous hemorrhage or when the view of the anterior capsule is compromised by dense cataract, corneal scarring or corneal edema [2]

We report two cases of iatrogenic toxic keratopathy secondary to inadvertent intrastromal trypan blue corneal staining during phacoemulsification surgeries performed by ophthalmology residents.

2 CASE REPORTS

2.1 Case 1

A 55-years-old woman with underlying diabetes mellitus and hypertension presented to ophthalmology clinic of Tengku Ampuan Afzan Hospital with bilateral blurring of vision. She was

diagnosed with bilateral eye cataract. Examination revealed visual acuity of 2/60 on the right eye and 6/36 on the left eye. Her right eye cataract was graded as posterior subcapsular cataract of 2+, nuclear sclerosis of 2+, while the left eye had nuclear sclerosis of 2+. She had history of pterygium excision with conjunctival graft transplant surgery in both eyes with no recurrence.

She was planned for right eye phacoemulsification and intraocular lens implantation surgery. Intraoperatively, trypan blue dye 0.06% (OptiBlu; Ophtech, India) was inadvertently injected into corneal stroma through the side port wound. The cornea was instantaneously stained blue and developed haziness. Anterior chamber (AC) was flushed with Balanced Salt Solution (BSS). The surgery was abandoned due to poor visualization. The wound was hydrated and secured using a 10.0 monofilament suture. Subconjunctival gentamicin and dexamethasone were given.

Postoperatively, best corrected visual acuity deteriorated to hand motion on the right eye. Slit

lamp examination of the right eye revealed central blue staining of the corneal stroma with a diameter of 5-6 mm tracking from the side port wound. There was limbal to limbal panstromal edema with marked corrugated Descemet membrane folds. Additionally, there were epithelial microbullae and mild circumcorneal injection (Figure 1). Intraocular pressure (IOP) was within the normal limit. Anterior segment optical coherence tomography showed diffuse corneal edema with a central corneal thickness of 740 micrometers. Specular microscopy could not be performed to assess the endothelium cells due to hazy media.

The affected eye was administered topical dexamethasone 0.1% drops hourly, chloramphenicol drops every 2 hours and hypertonic saline 5% drops 6 hourly. On the second day, the bluish stain on the cornea had reduced and localised at the nasal corneal region. By the 9th day, the blue stromal staining had resolved with a reduction of corneal edema (Figure 2). Her vision improved from hand motion to 1/60. Subsequently, topical steroids were tapered and discontinued after 6 weeks at which point in time, her corneal edema had resolved. The patient was scheduled for cataract surgery after 6 months.

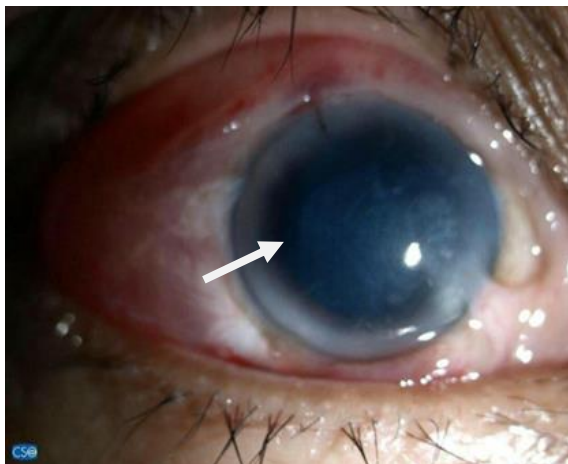


Figure 1: Right eye :Day 1 post surgery; marked corneal edema and Descemet striations with blue stain (arrow)

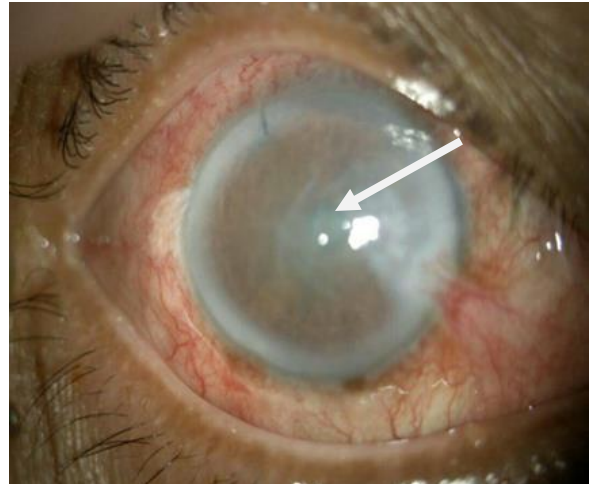


Figure 2: Day 2 post surgery; reduction of corneal edema (arrow).

2.2 Case 2

The second patient is a 63-year-old man with diabetes mellitus and hypertension who presented to our ophthalmology clinic with left eye blurring of vision for a year. He had a history of uneventful right eye cataract surgery two years prior. Examination revealed visual acuity of 6/12 on the right eye while his left eye vision was 6/36. His cataract was graded as posterior subcapsular cataract of 2+ and nuclear sclerosis of 3+. Other anterior segment and posterior segment examinations were normal. His IOP was normal and he had no diabetic retinopathy.

He was planned for left eye phacoemulsification and intraocular lens implantation surgery. Similar to the first case, trypan blue dye was inadvertently injected into the corneal stroma and AC through the side port wound. He developed diffuse corneal edema obscuring anterior chamber view and iris details. The anterior chamber was irrigated with 5ml of balanced salt solution. However, the surgery was abandoned due to the poor visualization.

Postoperatively, his visual acuity deteriorated to hand movement. Slit lamp examination of the left eye showed generalized corneal edema with Descemet folds in all quadrant. The bluish corneal staining was localised within the posterior stroma (Figure 3). There were pigmented keratic precipitates (KP) and fibrin in AC. IOP measured was 16 mmHg. He was diagnosed with left eye toxic anterior segment syndrome (TASS).

He was started on hourly topical

dexamethasone drops, 2 hourly topical ciprofloxacin, and 6 hourly hypertonic saline 5% drops. After 5 days, corneal clarity began to improve with reduction in number of KP. The AC reactions resolved after 2 weeks with residual segmental posterior synechiae formation. It took 6 weeks for total resolution of the corneal signs (Figure 4). The patient subsequently underwent uneventful cataract surgery 3 months later. His final visual acuity of the affected eye was 6/9.

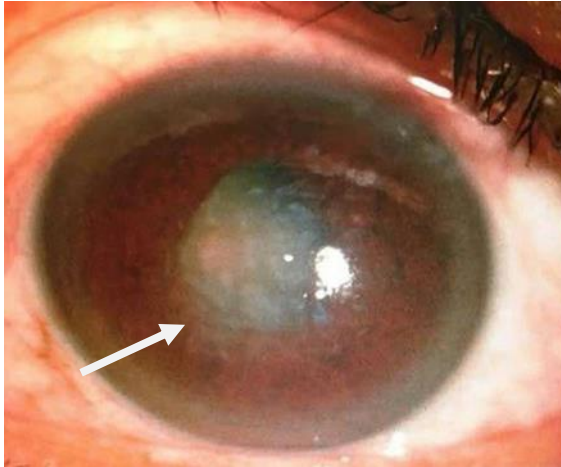


Figure 3: Day 2 post surgery; corneal edema with Descemet striations (arrows)

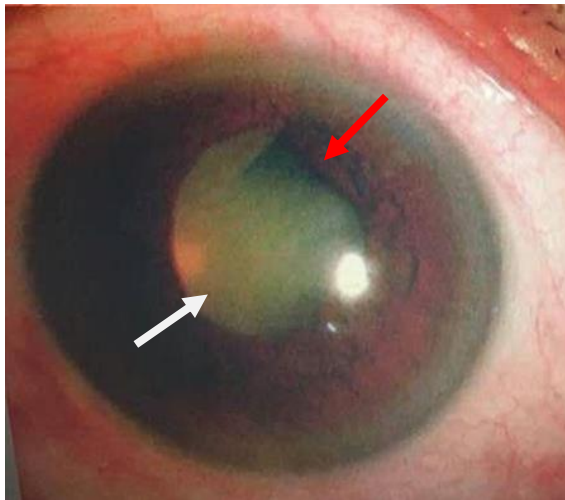

Figure 4: Resolved corneal injury (white arrow)
Posterior synechia formation (red arrow)

3 DISCUSSION

Trypan Blue (TB) is a large, very hydrophilic tetrasulfonated anionic azo dye [3]. It has been widely used since the 1990s in cataract surgeries to aid in visualization during capsulorhexis with relatively few reported complications [1].

Its safety profile has been reinforced in an in-vitro study on cultured rabbit's corneal endothelial cells, with various concentrations of trypan blue (0.01%, 0.10%, 0.20%, and 0.40%) which showed no endothelial cytotoxicity after 1-minute exposure [4]. The concentration used in both of our cases was 0.06%. There are a few studies and case reports published which reported on conflicts with its safety profile. Gouws et al reported an increased rate of cystoid macular edema (CME) associated with trypan blue use [5]. In this study, none of the patients who developed CME had associated posterior capsule rupture or ocular comorbidity. Inadvertent stromal staining and posterior capsule staining had been reported previously [2, 6]. In both reports, the resolution was seen within one to two weeks. Trypan blue 0.1% has also been reported to permanently stain hydrophilic intraocular lenses [6].

A report by Matsou et al. described 5 cases of TASS resulting from usage of generic trypan blue during cataract surgery [8]. The generic trypan blue agent was found to have a higher concentration of the active ingredient which would have caused the insult. All the patients reportedly improved with intensive steroid treatment and antibiotic cover. No permanent corneal damage or staining was seen during their follow up.

In both of our cases, the trypan blue had been inadvertently injected into the corneal stroma. Visualisation was an immediate issue and anterior chamber washout was a futile effort. The second patient was further complicated by TASS. It must be emphasized that although the trypan blue used was a generic, it is still within the safe concentration of 0.06% and safe volume of maximal 0.3ml. Apart from that, this trypan blue has been used for many years at our center without any other adverse event.

Both of the corneal injuries were largely contributed by improper technique and improper wound construction. In both cases, cornea wounds were constructed with long tunnel within the stroma which increased the chances of trypan blue being inadvertently injected into the stroma. We suggest that trypan blue is introduced into the anterior chamber via main wound rather than the side port wound as the access is wider and accessible to surgeon's dominant hand. This will aid in pivoting and manipulation of the cannula during insertion. We also suggest proper visualization of the cannula tip prior to injection of trypan blue into the anterior chamber. Several

methodologies for injecting the dye have been described, including beneath air, beneath ophthalmic surgical device (OVD), and mixing with an OVD, beneath OVD and BSS [1]. The method used in our setting is by injecting it directly into the AC (0.2-0.3ml) through the main wound and immediately flushing it out with BSS.

The mainstay treatment advocated in our patients were topical steroids. Steroid aids in reducing anterior segment inflammation through suppression of corneal lymphangiogenesis, by suppression of macrophage infiltration, pro-inflammatory cytokine expression and direct inhibition of proliferation of lymphatic endothelial cells [9]. It also helps to activate endothelial cell pump function which benefits in reducing corneal edema.

4 CONCLUSION

Although trypan blue has good safety profile, an inadvertent intrastromal trypan blue injection can induce toxic keratopathy which in some cases may manifest as TASS. Fortunately, it can be reversed with topical steroid and topical hypertonic saline without any permanent ocular damage. This condition is however avoidable by proper wound construction and pivoting technique with visualization of the cannula tip before introducing trypan blue into AC.

REFERENCES

- [1] Jhanji V, Chan E, Das S, Zhang H, Vajpayee RB. Trypan blue dye for anterior segment surgeries. *Eye*. 2011;25(9):1113-20.
- [2] Jhanji V, Agarwal T, Titiyal JS. Inadvertent corneal stromal staining by trypan blue during cataract surgery. *J Cataract Refract Surg*. 2008;34(1):161-2.
- [3] Badaro E, Novais EA, Penha FM, Maia M, Farah ME, Rodrigues EB. Vital dyes in ophthalmology: a chemical perspective. *Curr Eye Res*. 2014;39(7):649-58.
- [4] Chang YS, Tseng SY, Tseng SH. Comparison of dyes for cataract surgery. Part 2: efficacy of capsule staining in a rabbit model. *J Cataract Refract Surg*. 2005;31:799–804.
- [5] Gouws P, Merriman M, Goethals S, Simcock PR, Greenwood RJ, Wright G. Cystoid macular oedema with trypan blue use. *The British Journal of Ophthalmology*. 2004;88(10):1348-9.
- [6] Pelit A. Unintentional staining of the posterior lens capsule with trypan blue dye during phacoemulsification: case report. *Int Ophthalmol*. 2012;32(2):187-9.
- [7] Werner L, Apple DJ, Crema AS, Izak AM, Pandey SK, Trivedi RH, et al. Permanent blue discoloration of a hydrogel intraocular lens by intraoperative trypan blue. *J Cataract Refract Surg*. 2002;28(7):1279-86.
- [8] Matsou A, Tzamalīs A, Chalvatzis N, Mataftsi A, Tsinopoulos I, Brazitikos P. Generic trypan blue as possible cause of a cluster of toxic anterior segment

- syndrome cases after uneventful cataract surgery. *J Cataract Refract Surg*. 2017;43(6):848-52.
- [9] Costagliola C, Romano V, Forbice E, Angi M, Pascotto A, Boccia T, Semeraro F. Corneal oedema and its medical treatment. *Clin Exp Optom*. 2013;96(6):529–35