

Ghani Siti-Ilyana¹, Yi-Ni Koh¹, Embong Zunaina¹

Bilateral Jensen Disease In A Healthy Young Lady

¹Department of Ophthalmology, School of Medical Sciences, Health Campus, Universiti Sains Malaysia, 16150 Kubang Kerian, Kelantan, Malaysia

Abstract— Toxoplasmic optic neuropathy is rare and usually occurs monocularly. This case report demonstrates a rare presentation of bilateral juxtapapillary retinochoroiditis (Jensen disease) due to toxoplasma infection in a young healthy patient. A 20-year-old lady presented with bilateral painless blurring of central vision for 5 days duration. It was preceded by fever, upper respiratory tract symptoms and headache. There was no history of contact or being scratched by a cat. Visual acuity was counting fingers for the right eye and 6/45 for the left eye. There was presence of relative afferent pupillary defect in the right eye. Optic nerve functions were impaired bilaterally which was severe in the right eye. Both eyes showed the presence of mild anterior segment inflammation and vitritis. Fundus examination revealed juxtapapillary retinochoroiditis bilaterally with swollen optic disc. Optical coherence tomography (OCT) showed presence of intra-retinal and sub-retinal fluid at macular area bilaterally. Serology for anti-toxoplasma Immunoglobulin G (IgG) was positive with titre of 1450 IU/ml. Computed tomography scan (CT scan) of brain and orbit was normal. A diagnosis of bilateral juxtapapillary retinochoroiditis or Jensen disease was made. Oral azithromycin 500 mg daily and guttae prednisolone 4 hourly for 6 weeks was commenced. Oral prednisolone 50 mg daily (1 mg/kg/day) was added after completion of 1 week of antibiotic and was tapered down within 5 weeks. There was improvement of vision as early as 3 weeks post initiation of the treatment. Upon 6 weeks completing the treatment, her vision has improved to 6/7.5 on both eyes with resolution of optic disc swelling and sub-retinal fluid. Early recognition and initiation of treatment in toxoplasma infection associated with juxtapapillary retinochoroiditis usually result in good visual prognosis.

Received 29 Jan 2018.
Revised 20 Mac 2018.
Accepted 20 Apr 2018.
Published Online 01 June 2018

*Corresponding author:
Zunaina Embong
E-mail: zunaina@usm.my

Keywords— Jensen disease, Juxtapapillary retinochoroiditis, Ocular toxoplasmosis.

1 INTRODUCTION

Ocular toxoplasmosis, an important cause of visual impairment, is a disease caused by the protozoa *Toxoplasma gondii*. It most often presents as a focal necrotizing retinitis. It is generally associated with vitritis and often with anterior uveitis. Optic neuropathy represents a rare clinical entity of ocular toxoplasmosis [1]. It may be involved through direct invasion or contagious from distant retinochoroidal lesion. Bilateral eye involvement usually occurs in congenital toxoplasmosis and in the immunocompromised patient [2]. In Jensen disease, the retinochoroiditis lesion occurs in the juxtapapillary area causing optic disc swelling and is usually unilateral [1]. We report a rare case of bilateral optic disc involvement in ocular toxoplasmosis in a young and healthy patient.

2 CASE REPORT

A 20-year-old Malay female presented with bilateral painless blurring of vision for 5 days

duration. The blurring of vision mainly affected the central vision which was worst in the right eye. There was no eye redness, eye discharge, photophobia or floaters. It was preceded by fever, running nose, sore throat, and cough. However, there was no sputum or haemoptysis. It was also associated with a generalized headache but no nausea or vomiting. She had no neurological symptoms such as unconsciousness, convulsions, and motor or sensory defects. She did not have any high-risk behaviour and denied any joint pain, oral ulcer, skin rashes, or contact with a tuberculosis patient. There was no history of contact or being scratched by a cat.

Ocular examination revealed visual acuity of counting finger in the right eye and 6/45 in the left eye. There was the presence of relative afferent pupillary defect in the right eye. Optic nerve functions were impaired in both eyes but more severe in the right eye. Optic nerve function in the right eye showed red desaturation of 0/10, light brightness of 5/10 and Ishihara plate of 0/17.

While on the left eye, optic nerve function was mildly reduced with Ishihara plate of 15/17 and 8/10 for both red desaturation and light brightness. Amsler grid test revealed bilateral central scotoma. However, Humphrey visual field (HVF) test was not performed in view of bilateral poor vision.

Both eyes showed the presence of grade 2+ of anterior chamber cells. There was no keratic precipitate or hypopyon. Iris was normal with no iris nodule and clear lens. Fundus examination revealed mild (score 2) vitritis with no snowball or string of pearls. There was the presence of juxtapapillary retinochoroiditis with optic disc swelling bilaterally. The right fundus demonstrated whitish fluffy juxtapapillary retinochoroiditis lesions at the temporal, nasal and inferior region of the optic disc (Figure 1A). The optic disc was swollen with peripapillary retinal haemorrhages inferiorly. There was also the presence of two small foci of retinitis at supero-temporal of macular area. The left fundus showed whitish fluffy juxtapapillary retinochoroiditis lesion at the superior margin of the optic disc (Figure 1B). The optic disc was hyperemic and swollen. There was no retinochoroiditis at peripheral or other parts of the retina. There was no obvious vasculitis, retinal exudate or macular star and absence of any atrophic retinal scar in both eyes.

Optical coherence tomography (OCT) showed the presence of intra-retinal and sub-retinal fluid bilaterally at macular region [Figure 1C and 1D]. Systemic and neurological examination revealed normal findings.

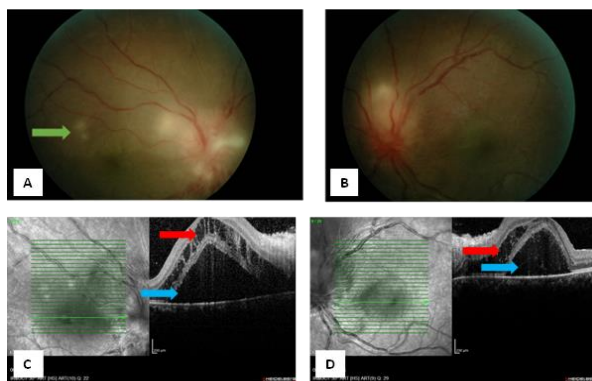


Figure 1: Right fundus photo showed juxtapapillary retinochoroiditis lesions with optic disc swelling and two small foci of retinitis at supero-temporal of macular area (green arrow) (1A). Left fundus showed juxtapapillary retinochoroiditis lesion at the superior margin of optic disc (1B). Optical coherence tomography showed the presence of intra-retinal fluid (red arrow) and sub-retinal fluid (blue arrow) bilaterally over macular region (right eye: 1C, left eye: 1D) at presentation.

A clinical diagnosis of bilateral infective uveitis was made based on the presence of vitritis and retinochoroiditis, which most likely toxoplasmosis in nature. The patient was treated with oral azithromycin 500 mg daily immediately (day 1 of admission) while waiting for blood infective screening results. Guttae prednisolone 4 hourly was added on day 2 of admission in order to control intraocular inflammation. Computed tomography (CT) scan of brain and orbit was performed in view of the presence of bilateral optic discs swelling in order to rule out any space occupying lesion.

Serological investigations showed anti-toxoplasma Immunoglobulin (Ig) G was positive with a titre of 1450 IU/ml. However, anti-toxoplasma IgM was negative. Other infective screenings were also negative [Table 1]. CT scan of brain and orbit was normal and the ventricles were not dilated with no mass or any space occupying lesion.

Table 1: Summary of infective screening

Investigations	Result
Full blood count	
White blood count	6.17x 10 ⁹ /l
Haemoglobin	11.6 g/dl
Platelet count	327x 10 ⁹ /l
Erythrocyte sedimentation rate	48mm/min
<i>Treponema pallidum</i> haemagglutination (TPHA) for syphilis	Non-reactive
Serology test for <i>Toxoplasma gondii</i>	
Anti-Toxoplasma IgM	Negative
Anti-Toxoplasma IgG	Positive; titer: 1450 IU/ml
Serology test for Cytomegalovirus IgM/IgG	Not detected
Serology test for <i>Herpes Simplex</i> virus 1 IgG	Non-reactive
Serology test for <i>Herpes Simplex</i> virus 2 IgG	Non-reactive
Mantoux test	0 mm

Based on positive serological test for *Toxoplasma gondii* and with the involvement of optic disc, a confirmatory diagnosis of bilateral juxtapapillary retinochoroiditis or Jensen disease was made. Oral azithromycin 500 mg daily and guttae prednisolone 4 hourly were continued for 6

weeks. After 1 week of treatment, there was improvement of vision in both eyes. Vision had improved to 6/90 for the right eye and 6/30 for the left eye. There was a reduction of anterior chamber cells and improvement of optic nerve functions bilaterally. However, the central scotomas were still present but less in severity. In view of optic nerve involvement, oral prednisolone 50 mg daily (1 mg/kg/day) was added with gradual tapering dose (tapered down 10 mg per week) within 5 weeks.

Three weeks after initiation of the treatment, her vision had further improved to 6/12 pinhole 6/9 in the right eye and 6/12 in the left eye with improvement of bilateral optic nerve functions. There was also resolution of anterior segment inflammation and vitritis. Fundus examination showed resolving of bilateral optic disc swelling and juxtapapillary retinochoroiditis with the presence of star-shaped hard exudates distributed at macular area in both eyes. There was mild macular star in the right eye (Figure 2A) and partial superior macular star in the left eye (Figure 2B). There was also resolving of supero-temporal retinitis in the right eye (Figure 2A). Repeated OCT also showed resolution of intra-retinal fluid bilaterally with complete resolution of sub-retinal fluid over the right eye and minimal residual sub-retinal fluid over the left eye (Figure 2C and 2D).

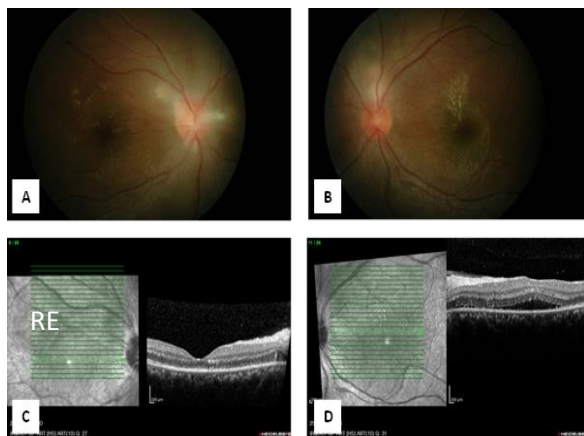


Figure 2: Fundus photo showed resolving of optic disc swelling and juxtapapillary retinochoroiditis bilaterally with the presence of bilateral hard exudate at macular area (right eye: 2A, left eye: 2B) and also resolving supero-temporal retinitis in the right eye (2A) after three weeks of treatment. Optical coherence tomography showed resolution of intra-retinal fluid bilaterally with complete resolution of subretinal fluid in the right eye (2C) and residual subretinal fluid in the left eye (2D).

Upon completing 6 weeks of treatment, her vision had significantly improved to 6/7.5 bilaterally. She

completely regained her optic nerve functions. Fundus examination showed complete resolution of optic disc swelling and healed retinochoroiditis bilaterally with residual hard exudate in the left eye (Figure 3). Repeated serology test for anti-toxoplasma IgG showed a reduction of titre from 1450 IU/ml to 1120 IU/ml.

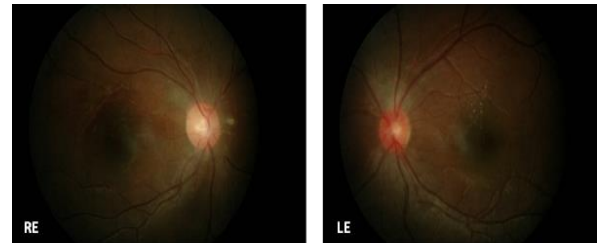


Figure 3: Fundus photo showed complete resolution of optic disc swelling and healed retinochoroiditis in both eyes (RE and LE) with residual hard exudate in the left eye (LE) after six weeks of treatment.

3 DISCUSSION

Toxoplasmosis, caused by the protozoan *Toxoplasma gondii*, affect healthy and immunocompromised people in many countries with over 6 billion people have been infected worldwide [3].

Ocular toxoplasmosis is one of the diseases caused by the infection through congenital or acquired routes [4]. It is one of the most frequent causes of posterior uveitis [2] and an important cause of visual impairment [5].

Ocular toxoplasmosis most often presents as granulomatous or non-granulomatous anterior uveitis with a focal necrotizing retinitis associated with vitritis [4]. In typical cases, active lesions are seen as whitish foci of retinochoroiditis, frequently adjacent to a pigmented and/or atrophic scar [4].

Rarely, *Toxoplasma gondii* may cause a lesion in the optic disc causing toxoplasmic optic neuropathy which often characterized by subacute visual loss and optic nerve swelling, and is sometimes associated with a macular star (neuroretinitis) [2]. This may occur via direct invasion or contiguous from retinochoroiditis lesion located far from the optic nerve [6]. The involvement of the optic nerve most frequently found in ocular toxoplasmosis was optic nerve oedema with a concurrent distant active lesion [6]. The second type of lesion most often found was juxtapapillary retinochoroiditis (Jensen Disease) [2]. The infection involves the choroid and retina, starts from the posterior end of the optic nerve sheaths [7]. Involvement of optic nerve usually monocular in most cases and the

visual prognosis was favourable with early treatment [2].

Our case presented with juxtapapillary retinochoroiditis causing bilateral optic disc swelling, which is a rare presentation. Bilateral eye involvement in ocular toxoplasmosis usually occurs in congenital toxoplasmosis or in an immunocompromised patient. In this case, since the patient was immunocompetent, there was a possibility that the patient acquired the infection congenitally. Congenital toxoplasmosis also has a wide spectrum of presentation and can be asymptomatic until the second or third decade of life. The lesions develop in the eye were presumably due to cyst rupture and subsequent release of tachyzoites and bradyzoites [8]. Recently acquired primary infection is also another possibility.

Clinically, it is impossible to differentiate between the late manifestation of congenital toxoplasmosis and primary acquired toxoplasmosis as both fundus showed no chorioretinal scar indicating previous infection. However, a study done by Yamamoto et al [9] showed that a patient with congenital infection can be discriminated from a patient with acquired infection based on T-cells response to toxoplasma antigen stimulation. Primary acquired ocular toxoplasmosis patients tend to have higher amounts of interleukin (IL)-1, tumour necrosis factor (TNF)- α , and IL-10 as compared to patient with late manifestation of congenital toxoplasmosis [9]. However, this test was not performed for our patient due to lack of laboratory facilities.

The diagnosis of ocular toxoplasmosis is usually based on typical clinical presentation. However, our patient presented with atypical feature of bilateral optic disc swelling. Thus, other causes of optic disc swelling should be considered as differential diagnosis. Causes of bilateral optic disc swelling can be due to space occupying lesion, other infectious causes such as syphilis, tuberculosis, herpes, and cytomegalovirus [10]. Sarcoidosis is one of the differential diagnosis of non-infective optic disc swelling [10]. When the clinical diagnosis cannot be made definitely by a funduscopic examination, radiological and serological tests may be needed to support the diagnosis [11]. Diagnosis for our patient was made based on the clinical finding which showed the presence of whitish fluffy active retinochoroiditis lesion adjacent to the optic disc and supported by markedly elevated IgG-specific antibodies for toxoplasmosis with a titre of 1450

IU/ml. However, specific IgM antibodies were not detected in this patient. IgM antibodies may appear earlier and decline more rapidly than IgG antibodies. In most cases, these titres become negative within a few months. Other infective causes were ruled out as their infective screenings were negative (Table 1). Intracranial and intraorbital causes of optic disc swelling were ruled out as the CT scan of the brain and orbit revealed normal findings.

Toxoplasma gondii antibody titers in ocular fluids or polymerase chain reaction (PCR) of aqueous and vitreous samples are other newer tools with high sensitivity and specificity to confirm the diagnosis [12]. However, these tests also were not performed for our patient in view of lack of laboratory facilities.

Ocular toxoplasmosis is a self-limiting disease. Treatment decision of toxoplasma induced retinal lesion would be made based on whether the lesion is within the temporal arcade, involving the optic nerve or threatening a large retinal vessel, when the lesion has induced a large degree of hemorrhage, or if there is a substantial two-line drop from the visual acuity before the acute infection [13]. In this case, the lesion was located at the juxtapapillary area causing optic neuropathy as well as substantial vitritis which required immediate treatment.

The combination of pyrimethamine, sulfadiazine, and corticosteroids with sometimes clindamycin added remains as the classic 'quadruple-drug therapy' [14]. In this case report, the patient was started on oral azithromycin 500 mg daily for 6 weeks. We considered azithromycin for the treatment of ocular toxoplasmosis because of its availability and limited toxicity. Studies [15, 16] showed that azithromycin of 250 mg or 500 mg can be used as a replacement for triple therapy and in fact had fewer side effects compared to the triple therapy regimen. Azithromycin is an effective alternative treatment with superior effect against cysts and bradyzoites in vitro if administered for longer than 4 weeks, and the median time for resolution of toxoplasmic retinal lesion is about 8 weeks [15]. It also crosses the blood-brain barrier and appears to be widely distributed to brain tissue as well.

The usage of corticosteroid in the treatment of ocular toxoplasmosis is controversial. No study has specifically evaluated the benefit of corticosteroid as an adjunct therapy to antimicrobials or as the sole medical approach for this disease [16]. In a healthy adult, the host immune response will contribute to the intraocular

inflammation that follows tachyzoite replication within the retina. Thus, for this reason, systemic corticosteroids are routinely added to the antimicrobial cocktail in immunocompetent adults with toxoplasmic retinochoroiditis. Systemic and topical corticosteroid was used to control the inflammation and to minimize chorioretinal damage. However, the timing of initiation of corticosteroids is important to balance the suppression of the immune response to the parasite while minimizing the disease severity [17]. The baseline indications for the use of corticosteroids include severe vitreous inflammation, decreased vision, and proximity of lesions to the fovea or optic disc and the large size of the active lesion [18]. For this patient, corticosteroid was started in view of the presence of juxtapapillary retinochoroiditis causing bilateral optic disc swelling leading to severe vision impairment. The systemic steroid was added after covering the patient with antiparasitic medication.

Fortunately, our patient has benefited from the treatment. Her condition improved dramatically following the initiation of the treatment. Upon completing her treatment, she gained a vision of 6/7.5 bilaterally. Although repeated toxoplasma serology upon completing treatment result was still high (more than 1000 IU/ml), it demonstrated a downtrend of the anti-toxoplasma IgG titre. This is because the anti-toxoplasma IgG titre usually peaks within 1 to 3 months and remains at a plateau level for 6 months. Then, the titre starts to decline after 1 year. The anti-toxoplasma IgG titre level does not correlate with the disease activity and explained why our patient had a good vision in spite of the high level of titre upon completing 6 weeks of her treatment. However, the patient must be reminded that recurrence rate is high even in a treated patient especially in the first year of most recent infection. Meanwhile, the issue of initiating chemoprophylaxis in certain patient as secondary prevention is still debatable.

4 CONCLUSION

Involvement of optic disc in ocular toxoplasmosis is rare. This case illustrated the rarity of ocular toxoplasmosis with bilateral optic disc involvement in a young and immunocompetent patient that accompanied with a high titre of anti-toxoplasma IgG. Early recognition and initiation of treatment resulted in good visual prognosis. However, long-term follow up is suggested since relapse or reactivation of the disease is common.

CONFLICTS OF INTEREST

No financial assistance was received for this study. The authors have no proprietary or financial interest in any product used or cited in this study

REFERENCES

- [1] Alipanahi R, Sayyahmelli S. Acute Papillitis in Young Female with Toxoplasmosis. *Middle East Afr J Ophthalmol*. 2011; 18(3):249-251. doi:10.4103/0974-9233.84060.
- [2] Eckert GU, Melamed J, Menegaz B. Optic nerve changes in ocular toxoplasmosis. *Eye*. 2007; 21(6):746-751.
- [3] Klaren VN, Kijlstra A. Toxoplasmosis, an overview with emphasis on ocular involvement. *Ocul Immunol Inflamm*. 2002; 10:1-26.
- [4] Park YH, Nam HW. Clinical Features and Treatment of Ocular Toxoplasmosis. *Korean J Parasitol*. 2013; 51(4):393-399. doi:10.3347/kjp.2013.51.4.393.
- [5] Wilking H, Thamm M, Stark K, Aebischer T, Seeber F. Prevalence, incidence estimations, and risk factors of *Toxoplasma gondii* infection in Germany: a representative, cross-sectional, serological study. *Sci Rep*. 2016; 6:22551. doi:10.1038/srep22551.
- [6] Banta JT, Davis JL, Lam BL. Presumed toxoplasmic anterior optic neuropathy. *Ocul Immunol Inflamm*. 2002; 10(3):201-211.
- [7] Jensen, E. Retinochoroiditis Juxtapapillaris. *Arch Ophthalmol*. 1908; 69: 41.
- [8] McAuley JB. Congenital Toxoplasmosis. *J Pediatric Infect Dis Soc*. 2014; 3(Suppl 1): S30-S35. doi:10.1093/jpids/piu077.
- [9] Yamamoto JH, Vallochi AL, Silveira C, Filho JK, Nussenblatt RB, et al. Discrimination between patients with acquired toxoplasmosis and congenital toxoplasmosis on the basis of the immune response to parasite antigen. *J Infect Dis*. 2000; 181(6):2018-22.
- [10] Elkins BS, Holland GN, Opremcak EM. Ocular toxoplasmosis misdiagnosed as CMV retinopathy in immunocompromised patients. *Ophthalmol*. 1994; 101:499-507.
- [11] Harper TW, Miller D, Schiffman JC, Davis JL. Polymerase chain reaction analysis of aqueous and vitreous specimens in the diagnosis of posterior segment infectious uveitis. *Am J Ophthalmol*. 2009; 147:140-147. e2. doi: 10.1016/j.ajo.2008.07.043.
- [12] Rothova A, de Boer JH, Ten Dam-van Loon NH, Postma G, de Visser L, et al. Usefulness of aqueous humor analysis for the diagnosis of posterior uveitis. *Ophthalmology*. 2008; 115(2):306-311. doi:10.1016/j.ophtha.2007.05.014.
- [13] Holland GN. Ocular toxoplasmosis: A global reassessment. Part II: disease manifestations and management. *Am J Ophthalmol*. 2004; 137(1):1-17.
- [14] Eyles DE, Coleman N. Antibiotics in the treatment of toxoplasmosis. *Am J Trop Med Hyg*. 1953; 2(1):64-69.
- [15] Rothova A, Bosch-Driessen LE, van Loon NH, Treffers WF. Azithromycin for ocular toxoplasmosis. *Br J Ophthalmol*. 1998; 82(11):1306-1308. doi.org/10.1136/bjo.82.11.1306.
- [16] Balaskas K, Vaudaux J, Boillat-Blanco N, Guex-Crosier Y. Azithromycin versus sulfadiazine and pyrimethamine for non-vision threatening toxoplasmic

- retinochoroiditis: a pilot study. *Med Sci Monit.* 2012; 18(5): CR296-302.
- [17] Bosch-Driessen EH, Rothova A. Sense and nonsense of corticosteroid administration in the treatment of ocular toxoplasmosis. *Br J Ophthalmol.* 1998; 82:858–60.
- [18] Oray M, Ozdal PC, Cebeci Z, Kir N, Tugal-Tutkun I. Fulminant ocular toxoplasmosis: the hazards of corticosteroid monotherapy. *Ocul Immunol Inflamm.* 2016; 24(6):637-646. doi:10.3109/09273948.2015.1057599.
- [19] Holland GN, Lewis KG: An update on current practices in the management of ocular toxoplasmosis. *Am J Ophthalmol.* 2002; 134(1):102-114.