

Jeyarine Royan¹,
Khairy Shamel Sonny Teo¹,
Selva Raja Vengadasalam²

Intralenticular matchstick in a toddler: A rare presentation of penetrating ocular injury from a toy gun

¹Department of
Ophthalmology, School of
Medical Sciences, Health
Campus Universiti Sains
Malaysia, 16150 Kubang
Kerian, Kelantan, Malaysia

²Hospital Selayang, 68100
Selangor, Malaysia

Abstract— To report on a rare case of an intralenticular foreign body which demonstrates that use of a spring-powered airsoft gun can result in a severe ocular injury. A 2-year-old male presented following a trauma to the left eye. The trauma was caused by a wooden matchstick from a spring-powered airsoft gun being shot into his eye. On examination, there was a shallow anterior chamber with a full thickness corneal laceration, with fragmented matchstick pieces embedded in the cornea and in the lens. The corneal foreign bodies were removed, corneal laceration wound sutured and lensectomy done. There were no post-operative complications, and the cornea wound healed with a scar. A few months later, he underwent a successful secondary intraocular lens implantation surgery with an iris claw lens. Airsoft guns are easily available to children who are unaware of its dangers. It can cause significant ocular morbidity despite successful surgical treatment of the injury.

Received 21 Jan 2018.
Revised 12 Apr 2018.
Accepted 20 Apr 2018.
Published Online 01 June 2018

Keywords – Intralenticular Foreign Body, Ocular Injury, Toy Gun

*Corresponding author:
Jeyarine Royan
E-mail: jeyarineroyan@yahoo.com

1 INTRODUCTION

Ocular trauma remains a significant cause of preventable blindness. A common association of ocular trauma is retained intraocular foreign body (IOFB). IOFBs can lodge anywhere in the eye, including in the anterior or posterior segments. Some types of retained IOFBs may be inert and harmless to the eye, but others can cause persistent ocular inflammation and severe eye infections such as endophthalmitis. A study conducted in the United Kingdom [1] reported that IOFBs may result in a severe visual loss in as many as 22% of cases.

Airsoft guns are easily available and as a result, young children often have easy access to such toys. According to Keller et al. [2], when fired at close range, airsoft guns can potentially cause similar tissue penetration as most small-caliber handguns.

In a 10-year retrospective case series evaluating the ocular injuries sustained by airsoft guns, Jovanović et al. [3] observed a wide range of injuries affecting both anterior and posterior segments, such as subconjunctival hemorrhage, corneal abrasion, hyphema, high intraocular pressure, traumatic cataract, vitreous and retinal hemorrhages, and even a case of globe rupture. In

a separate case series evaluating airsoft gun injuries over a 2-year period, Fleischhauer et al. [4] observed injuries ranging from light contusions to sight-threatening globe injuries. The data suggests that a small, cheap innocuous toy can cause severe ocular morbidity.

According to Rathod et al. [5], only 8 percent of intraocular foreign bodies are lodged in the lens; the commoner sites of lodgement being the anterior chamber, vitreous and retina. Intralenticular foreign bodies are relatively rare in comparison to other locations in the eye.

We report a case of a spring-powered airsoft gun injury in a 2-year-old male which caused a rare ocular injury of retained IOFB in the lens. Although this was treated swiftly, the potential for poor visual outcome remains due to the risk of amblyopia in a developing eye.

2 CASE REPORT

A 2-year-old male presented following an alleged trauma to the left eye. The trauma was alleged to have been caused by the patient's older brother shooting the patient's eye at their home using a small spring-powered plastic airsoft gun. (Fig. 1).

The ammunition used was a matchstick. The only witness present attested that a loud explosion was heard when the gun was fired.

On examination, the patient presented a linear full thickness corneal laceration wound with uveal prolapse. A wood piece was embedded in the temporal aspect of the cornea. There was also blood in the anterior chamber (hyphema) and the lens appeared cataractous.

Plain CT orbit demonstrated air pockets in the anterior segment but no intraocular or intraorbital foreign body.

He was immediately posted for emergency surgery. The patient's mother was informed that the aim of the primary surgery was to stabilize the wound and that there was a cataract which may also require subsequent surgery and secondary implantation of an intraocular lens later. She was also informed of the guarded visual prognosis given the nature and extent of the injury, possible development of amblyopia and the need for visual rehabilitation and long-term follow up once the acute injury had been treated.

The patient underwent an examination under anesthesia. Intraoperative findings revealed a shallow anterior chamber with a full thickness corneal laceration with macerated edges and iris plugging. There were fragmented matchstick pieces embedded in the cornea. The lens was cataractous with no obvious capsular breach; however, the view was limited due to the corneal haze. The anterior chamber was maintained intraoperatively using a viscosurgical device. The corneal foreign bodies were meticulously removed and the corneal laceration wound sutured with Nylon 10-0 sutures. Post suturing, the wound was stable, as evidenced by a negative Seidel's test. The surgery was completed by giving intravitreal injections of *Vancomycin* & *Ceftazidime*.

On the first post-operative day, the anterior chamber was shallow with a leak from the corneal wound. As a result, the patient was posted for a second surgery. Intraoperatively, a large fragment of matchstick was seen intralenticularly and removed (Fig. 2). This matchstick piece may have been overlooked on the first surgery as it was embedded inside the lens and externally there was no obvious capsular breach. The poor corneal clarity could have also contributed to the intralenticular matchstick piece being missed.

To clear the cataractous lens, a lensectomy was performed and the cornea wound resutured using Nylon 10-0 sutures. Post-operative examination of the vitreous and retina and optic nerve was normal, and topical steroid (*Gutt*

dexamethasone) and antibiotic (*Gutt moxifloxacin*) drops were administered to the patient on a two-hourly basis for the rest of his admission. There were no post-operative complications. The subsequent findings in the eye was an eccentric pupil, with healed corneal scars.

A few months later, the patient successfully underwent a secondary intraocular lens implantation surgery with an iris claw lens. His post-operative visual acuity was 6/12 in the right eye and 6/500 in the left eye. There was a corneal scar superonasally from the previous laceration wound and the intraocular pressure was normal. There was no anterior chamber inflammation, and the iris claw lens was stable. The retina, macula and optic disc was normal. He was diagnosed with left eye amblyopia post-treated penetrating ocular injury and he was started on regular patching therapy for the right eye.

There was history of poor compliance to patching. During his follow-up it was reinforced to the parents regarding the need for patching over the right eye for 2 to 3 hours' day; ideally with an electronic device as a positive reinforcement only during patching.



Figure 1: Photograph of the airsoft toy gun which caused the injury

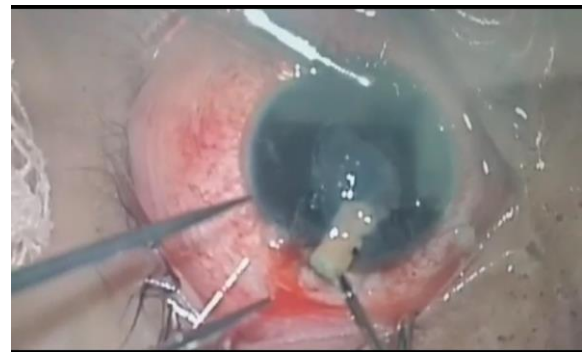


Figure 2: Photograph of the anterior segment showing the matchstick fragment being removed from the eye during surgery

3 DISCUSSION

Airsoft guns are known to cause ocular injuries, and their effects on the eye have been documented in studies or case reports from many countries [3-4,6-7]. This indicates a global problem of traumatic ocular injuries secondary to airsoft guns, which in our and others' view, is easily preventable.

To our knowledge, our case report is the first reported case of injury caused by a matchstick being used as ammunition for an airsoft gun, and the first reported case of an intralenticular matchstick fragment due to a toy gun injury.

Based on the literature we reviewed [3-4], the ocular injuries sustained by airsoft guns can range from corneal abrasions and cornea contusions to high intraocular pressure, traumatic cataract (with or without capsular breach), traumatic mydriasis and iridodialysis. The same literature indicated that the posterior segment was rarely involved, which was also observed in this case. The most common injury sustained was hyphema. [4,6,8]. This case demonstrated the findings of a blunt injury such as hyphema and cataract which is also combined with a penetrating injury as evidenced by the corneal laceration wound.

As Fleischhauer et al. [4] uncontroversially stated, airsoft guns are easily available and their sale is not restricted by age. In Malaysia (where this case presented), such guns can be purchased at roadside stalls and open markets relatively inexpensively, with no age restrictions, making them easily available to young children. They can also be purchased online. These toys which can be easily purchased, may not have a proper instruction manual or age limit. For example, in this case, the patient's brother had found the toy gun on the roadside near his school.

In a retrospective review of 33 patients who suffered ocular injuries from airsoft guns in Denmark, the mean age of patients was 13 years, with only one toddler (a 3-year old) sustaining an ocular injury. [8]

Shazly et al. [9] reported that in 75 percent of the cases of pediatric airsoft gun injuries they studied the toy gun was fired by a family member or friend, and in 100 percent of those cases, the injuries occurred in the home.

The offending air gun, in this case, was spring-powered: it used the latent energy stored in a compressed spring to propel the matchstick out of the barrel of the gun. In this case, the assailant used a different ammunition (matchstick instead of pellets) and fired the victim at a close range. Since

a matchstick was used as the ammunition, there was a combination of blunt and penetrating ocular injury. The blunt force was caused by the high impact due to firing at a close range causing hyphema and possibly a traumatic cataract whereas the penetrating injury was due to sharp matchstick pieces penetrating the globe and lodging in the cornea and crystalline lens.

The child presented early, which allowed for the quick initiation of treatment preventing further damage, inflammation and reducing the risk of infection. The combination of a healing corneal wound and aphakia for several months before a secondary lens implantation was performed posed an amblyogenic threat due to the difference in refractive power between the eyes. This is reflected in the poor visual acuity in the left eye even with an intraocular lens in situ and normal structural integrity of the eye as evidenced by healthy optic nerve, retina and vitreous. Patching and visual rehabilitation may help to diminish this risk; however, it requires continuous motivation and cooperation from both parents and the patient which may not be possible on a long-term basis.

There remains the need for stricter control of toy airsoft guns in children to prevent ocular injuries. The usage and sale of these toys should be age restricted and clear instructions on the recommended use of safety goggles and parental/adult supervision should be written on the product manual. They should also not be freely available in the local markets and shops and there should be more awareness and education among consumers, particularly parents. In Malaysia, the Ministry of Domestic Trade, Co-operatives and Consumerism (MDTCC) is the responsible authority on toys and the enforcement of safety regulations, particularly for vulnerable groups [10].

In the United Kingdom, children below the age of 14 can use an air weapon if supervised by a person over the age of 21. [11]. According to Shuttleworth et al., [11] many air gun injuries still occur despite the presence of existing laws; they suggest that restricting the access and ownership of airguns may help reduce the incidence of these injuries.

4 CONCLUSION

While toy airsoft guns may appear harmless, when used incorrectly or carelessly or without sufficient protective equipment, they have the potential to cause significant ocular injuries, particularly in young children who are at a risk of developing amblyopia. There is a need for more caution, warning, and education for parents, children and

healthcare professionals alike to reduce the incidence of ocular airsoft gun injuries.

CONFLICTS OF INTEREST

The authors report no conflicts of interest. The authors alone are responsible for the content and writing of the paper.

ACKNOWLEDGEMENT

Author(s) certify that they have no affiliation with or significant financial involvement in any organizations or entity with a direct financial interest in the subject matter or materials discussed in the manuscript on this page.

REFERENCES

- [1] Imrie F, Cox A, Foot B, et al. *Surveillance of intraocular foreign bodies in the UK*. Eye (London, England) [serial on the Internet]. (2008, Sep), [cited December 19, 2017]; 22(9): 1141-1147. Available from: MEDLINE with Full Text.
- [2] Keller J, Hindman J, Kidd J, et al. *Air-Gun Injuries: Initial Evaluation and Resultant Morbidity*. American Surgeon [serial on the Internet]. (2004, June), [cited December 19, 2017]; 70(6): 484-490. Available from: Academic Search Complete.
- [3] Jovanović M, Bobić-Radovanović A, Vuković D, et al. *Ocular injuries caused by airsoft guns - ten-year experience*. Acta Chirurgica Iugoslavica [serial on the Internet]. (2012), [cited December 19, 2017]; 59(3): 73-76. Available from: MEDLINE with Full Text.
- [4] Fleischhauer J, Goldblum D, Frueh B, et al. *Ocular injuries caused by airsoft guns*. Archives of Ophthalmology (Chicago, Ill.: 1960) [serial on the Internet]. (1999, Oct), [cited December 19, 2017]; 117(10): 1437-1439. Available from: MEDLINE with Full Text.
- [5] Rathod R, Mieler W, et al. *An Update on the Management of Intraocular Foreign Bodies*. Retinal Physician [serial on the Internet]. (2011, Apr), [cited March 12, 2018]; 8(3): 52. Available from: Supplemental Index.
- [6] Ramstead C, Ng M, Rudnisky C. *Ocular injuries associated with Airsoft guns: a case series*. Canadian Journal Of Ophthalmology [serial on the Internet]. (2008, Oct), [cited December 19, 2017]; 43(5): 584. Available from: Supplemental Index.
- [7] Endo S, Ishida N, Yamaguchi T. *Tear in the trabecular meshwork caused by an airsoft gun*. American Journal Of Ophthalmology [serial on the Internet]. (2001, May), [cited December 19, 2017]; 131(5): 656-657. Available from: MEDLINE with Full Text.
- [8] Saunte J, Saunte M. *33 cases of airsoft gun pellet ocular injuries in Copenhagen, Denmark, 1998–2002*. Acta Ophthalmologica Scandinavica [serial on the Internet]. (2006, Dec), [cited December 19, 2017]; 84(6): 755-758. Available from: Academic Search Complete.
- [9] Shazly T, Al-Hussaini A. *Pediatric Ocular Injuries From Airsoft Toy Guns*. Journal Of Pediatric Ophthalmology & Strabismus [serial on the Internet]. (2012, Jan), [cited December 19, 2017]; 49(1): 54. Available from: Complementary Index.
- [10] Portal Rasmi MyStandard. [cited 21 Mar 2018]. Available from:

- https://mystandard.kpdnkk.gov.my/mystandard_portal2014/index.php?f=column/ctwo&id=25
- [11] Shuttleworth GN, Galloway PH. *Ocular Air-Gun Injury: 19 Cases*. Journal of the Royal Society of Medicine. (2001, Aug) [cited 21 Mar 2018].;94(8):396–9. Available from: MEDLINE with Full Text.