

Adam M¹, Muhammad Nasri AB², Arfahiza S³, Irfan M¹

Laryngopharyngeal Tuberculosis Mimicking Hypopharyngeal Carcinoma

¹Department of Otorhinolaryngology-Head & Neck Surgery, School of Medical Sciences, Universiti Sains Malaysia Health Campus, 16150 Kota Bharu, Kelantan, Malaysia

²Department of Otorhinolaryngology, Hospital Tengku Ampuan Afzan, 25100 Kuantan, Pahang, Malaysia

³Department of Pathology, Hospital Tengku Ampuan Afzan, 25100 Kuantan, Pahang, Malaysia

Abstract— Laryngopharyngeal tuberculosis (TB) is a rare disease and usually associated with pulmonary tuberculosis. Mostly, it occurs in adults without BCG vaccination or in immuno-compromised patients (such as AIDS patients). A 34-year-old gentleman with odynophagia and poor oral intake was referred to us to rule out malignancy. Direct laryngoscopy examination revealed ulcerative lesion involving right tonsillar fossa extending downward till right pyriform sinus. Panendoscopy and biopsy was performed. Laryngopharyngeal TB was diagnosed based on the histopathological examination and Ziehl-Neelsen staining.

Received 21 Dec 2017
Revised 06 Feb 2018.
Accepted 05 Mac 2018.
Published Online 01 June 2018

Keywords: Laryngopharyngeal Tuberculosis, Ziehl-Neelsen staining, odynophagia

*Corresponding author:
Adam Mohamad
E-mail: persona522115@gmail.com

INTRODUCTION

Tuberculosis (TB) commonly affect the pulmonary region(1). It can also affect other organs and tissues such as lymphatic, genitourinary, bone, joint, central nervous system, peritoneal, abdominal organs as well as head and neck region(2). Extrapulmonary TB occurrence in the world is reported approximately 25 %, of which 10-35% were found in the head and neck region(3). Common sites include lymph node, cervical spine, parotid, tongue, hard palate, soft palate, temporomandibular joint, tonsil and larynx(4). Laryngopharyngeal TB is an uncommon form of TB infection which usually present with odynophagia, dysphagia and at times hoarseness when involving the vocal cord(5). Most of the time, it occurs in the presence of pulmonary or systemic infection whereby the route of infection is hematogenous or via lymphatic spread. Primary pharyngeal TB is otherwise rare and is postulated as a result of direct infection of the upper respiratory tract(6).

Confusingly, it has a clinical picture almost equal to that of pharyngeal carcinoma whereby both came with cervical lymphadenopathy, sore throat and odynophagia. Given its rare occurrence, it is crucial for us to be familiar and aware of the presentation and further investigations.

CASE REPORT

A 34-year-old Malay gentleman presented with odynophagia with reduced oral intake for 5 months duration. Initially he sought various treatments for unhealed ulcer at right tonsillar area. It was associated with low grade fever, loss of appetite and significant loss of weight of 12 kg within that period. He is an ex-smoker, 1 pack per day for 20 years however claimed had stopped smoking 3 months previously. He denied of hemoptysis, noisy breathing, and change of voice or pain on moving the tongue. On further questioning, he had multiple small neck nodes swelling on both side and occasional productive

cough with yellowish sputum. He had never been admitted to a hospital. He denied of using recreational drug and was non-alcoholic. There was no family history of malignancy. He had positive history of TB contact recently which was his neighbour who was undergoing treatment.

On examination, the patient was alert and conscious. There was no stridor. He was afebrile, and not tachycardic. There were multiple small shotty lymph nodes at level II, III, IV at both sides of neck, mobile, not fixed to surrounding structures and not tender. On auscultation, air entry was equal on both lungs. Otoloscopic examination revealed normal ear canals and tympanic membrane. Upon nasoendoscopy, the nasal mucosa was normal, no mass seen and the fossa of Rosenmuller was not obliterated. There was no trismus. On direct laryngoscopy, there were ulcerative lesions at posterior wall of oropharynx, right tonsillar fossa, epiglottis, pyriform sinus and right arytenoid. The vocal cords were otherwise mobile with no phonation gap. The posterior commissure was normal.

His chest radiograph revealed diffuse patchy consolidation involving both lung fields. Upon computed tomography (CT) of neck and thorax, there were slight irregularity and fullness at the left lateral pharyngeal wall extending close to left pyriform sinus (Figure 1). There was no evidence of enhancement or mass lesion seen. The arytenoid cartilage was not thickened. Parapharyngeal space and pyriform sinus were not obliterated. Apart from that, there were multiple subcentimeter cervical lymph nodes seen at level I-VI, the largest measuring 0.7 cm. The vocal cord was symmetrical. Interestingly, diffuse tree-in-bud appearance (suggestive of endobronchial TB) and consolidation with cavitations were seen in both lungs and subcentimeter mediastinal lymph nodes (up to 0.6 cm) seen in paratracheal as well as aortopulmonary regions. Laboratory investigations revealed negative sputum for acid fast bacilli (AFB) as well as negative viral screening for hepatitis B, C and HIV.

He underwent panendoscopy and biopsy. Tissues from right tonsil, right side of epiglottis, right base of tongue, right pyriform sinus, right arytenoid and posterior pharyngeal wall were taken and sent for urgent histopathological examination (HPE). Presence of acid fast bacilli

on Ziehl-Neelsen staining confirmed the diagnosis of laryngopharyngeal TB (Figure 2).

He was referred to chest physician and currently on tablets isoniazide 75 mg once daily (OD), rifampicin 150 mg OD, pyrazinamide 400 mg OD, ethambutol 275 mg OD and pyrazinamide 20 mg OD. He was planned for 2 months intensive course of treatment followed with maintenance phase which consist of tablets isoniazide 75 mg OD and rifampicin 150 mg OD for following 4 months. Now the patient is on maintenance phase of anti TB and scheduled for next follow up right after completion of the therapy.

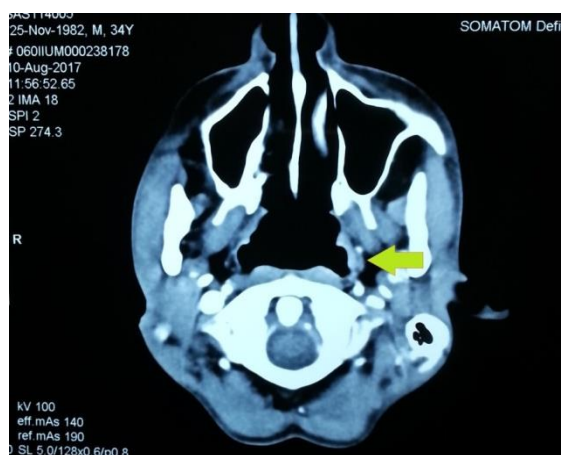


Figure 1: Neck region CT of the patient showing irregularity and fullness at left lateral pharyngeal wall (arrow).

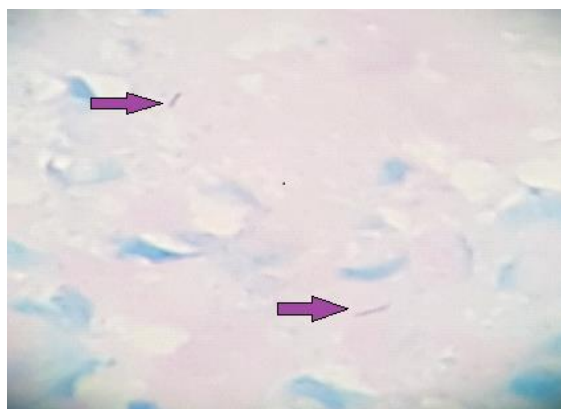


Figure 2: Ziehl-Neelsen stain show presence of acid fast bacilli (arrow) in tissue sample taken from the right base of the tongue. (Magnification x 630)

DISCUSSION

Tuberculosis (TB) seldom develops in the head and neck region, where it is usually present with lymphadenitis. Pharyngeal involvement appeared

in less than 1% of patients with head and neck tuberculous infections(7). In cases of pharyngeal TB, odynophagia, dysphagia, sore throat, cervical lymphadenopathy and hoarseness are the major symptoms due to pharyngeal or laryngeal involvements(8) which are usually accompanied by systemic complaints such as fever, night sweats and weight loss. Confusingly, all these symptoms are also common in pharyngeal or laryngeal carcinoma cases.

The diagnosis of laryngopharyngeal TB is made on the basis of microbiologic and pathologic findings of the biopsied samples. Previously, laryngeal TB was usually associated with advanced pulmonary infection and the mode of infection was due to direct spread along the airway passages via secretions affecting mostly the posterior commissure of vocal cord(9). Surprisingly, in our case the posterior commissure was unaffected. The radiological investigation such as CT and magnetic resonance imaging (MRI) are reportedly valuable tools in head and neck TB, giving the sites, pattern and extent of the disease(10). In our case, CT scan images showed findings highly suggestive of a diagnosis of TB.

Generally, the treatment of extrapulmonary tuberculosis (EPTB) is still anti-TB regime and all EPTB is treated with anti-TB chemotherapy for a minimum of 6 months duration. The prognosis is good provided the patient completed the treatment regime. In this case the most likely source of spread was likely due to his contact from active pulmonary TB patient whereby direct infection to the mucosa of laryngopharyngeal region occur via aerosolized particles. Primary involvement such as this case is rarely reported (11).

CONCLUSION

The presentation of extrapulmonary TB is rare as compared to pulmonary TB. Nevertheless, the presentation can mimic other entities. Thus, it is very important to have a high index of suspicion to rule out TB, given that it is a curable disease, as late diagnosis will lead to high morbidity and mortality. With the neck node presentation, the differential diagnosis of hypopharyngeal carcinoma must be ruled out with endoscopy and biopsy of the intraluminal lesions before any open procedure is made on the neck nodes.

CONFLICTS OF INTEREST

The authors report no conflicts of interest. The authors alone are responsible for the content and writing of the paper.

REFERENCES

- [1]. Erbaycu A, Taymaz Z, Tuksavul F, Afrashi A, Güçlü S. What happens when oral tuberculosis is not treated? *Monaldi Archives for Chest Disease*. 2016;67(2):116-8.
- [2]. De Backer A, Mortelet K, De Keulenaer B, Parizel P. Tuberculosis: epidemiology, manifestations, and the value of medical imaging in diagnosis. *Journal Belge de Radiologie - Belgisch Tijdschrift voor Radiologie*. 2006;89(5):243.
- [3]. Vaid S, Lee Y, Rawat S, Luthra A, Shah D, Ahuja A. Tuberculosis in the head and neck—a forgotten differential diagnosis. *Clinical Radiology*. 2010;65(1):73-81.
- [4]. Prasad KC, Sreedharan S, Chakravarthy Y, Prasad SC. Tuberculosis in the head and neck: experience in India. *The Journal of Laryngology & Otology*. 2007;121(10):979-85.
- [5]. Ricciardiello F, Martufi S, Cardone M, Cavaliere M, D'errico P, Iengo M. Otorhinolaryngology-related tuberculosis. *Acta Otorhinolaryngologica Italica*. 2006;26(1):38.
- [6]. Ito K, Morooka M, Kubota K. 18F-FDG PET/CT findings of pharyngeal tuberculosis. *Annals of Nuclear Medicine*. 2010;24(6):493-6.
- [7]. Nalini B, Vinayak S. Tuberculosis in ear, nose, and throat practice: its presentation and diagnosis. *American Journal of Otolaryngology*. 2006;27(1):39-45.
- [8]. Belizna C, Kerleau J, Heron F, Lévesque H. Tonsillar and lymph node tuberculosis revealing asymptomatic pulmonary tuberculosis. *QJM: An International Journal of Medicine*. 2007;100(12):800-1.
- [9]. Kenmochi M, Ohashi T, Nishino H, Sato S, Tanaka Y, Koizuka I, et al. A case report of difficult diagnosis in the patient with advanced laryngeal tuberculosis. *Auris Nasus Larynx*. 2003;30:131-4.
- [10]. Moon WK, Han MH, Chang KH, Im J-G, Kim H-J, Sung KJ, et al. CT and MR imaging of head and neck tuberculosis. *Radiographics*. 1997;17(2):391-402.
- [11]. Singh K, Kaur G, Parmar T. Pseudo tumoral laryngeal tuberculosis. *Indian Pediatrics*. 2003;40(1):49-51.